



The Canadian Association of Radiologists and the Canadian Society on Thoracic Radiology's Statement on COVID-19 Management in Imaging Departments

March 20, 2020

The purpose of this statement is to provide guidance and information to the radiology community regarding the diagnosis and treatment of COVID-19. The recommendations included in this document are subject to change given the rapid evolution of the COVID-19 pandemic outbreak. Interim guidance has been issued by the [World Health Organization](#) and by the United States' [Centers for Disease Control and Prevention](#) [2,3]. Links to these and other related society guidelines are found elsewhere (['Society guideline links'](#)).

The Canadian Association of Radiologists would like to acknowledge our Board of Directors who provided the direction for these recommendations.

1. Patient screening

All Radiology front desk reception areas need to screen patients by asking standardized questions. These are hard stop questions **that must be answered** before registration is completed. The current COVID-19 criteria for persons under investigation include¹:

- Fever or signs/symptoms of lower respiratory illness (cough/shortness of breath)
- Fever with severe acute respiratory illness (i.e. pneumonia, RDS) requiring hospitalization without explanatory diagnosis (i.e. influenza)
- Any person who has close contact with a laboratory confirmed COVID-19 patient(s) within 14 days
- History of travel outside Canada

If any of these criteria are positive, the requisition must be reviewed by a radiologist. If the imaging examination is clinically justified in a short delay, the patient should be managed as a potential COVID-19 patient.

2. Imaging findings and recommendation from the American College of Radiology (ACR), Canadian Association of Radiologist (CAR) and Canadian Society of Thoracic Radiology (CSTR)^{2,3}

- The Centers for Disease Control (CDC) does not currently recommend CXR or CT to diagnose COVID-19. **Viral testing remains the only specific method of diagnosis.** Confirmation with the viral test is required, even if radiologic findings are suggestive of COVID-19 on CXR or CT.
- **Generally, the findings on chest imaging in COVID-19 are not specific, and overlap with other infections.**⁴⁻⁶

- Imaging should only be conducted for those COVID-19 patients where imaging will impact management of the condition.
- **Facilities may consider deploying portable radiography units in ambulatory care facilities and or long-term care homes for use when CXRs are considered medically necessary.**^{1,7} The surfaces of these machines can be easily cleaned, avoiding the need to bring patients into radiography rooms, thus minimizing the spread of infection in larger healthcare institutions.
- As an interim measure, until more widespread COVID-19 testing is available, some medical practices are using chest CT to inform decisions on whether to test a patient for COVID-19. The ACR and CAR strongly urges caution in taking this approach. **A normal chest CT does not mean a person does not have COVID-19 infection - and an abnormal CT is not specific for diagnosis. A normal CT should not dissuade a patient from being quarantined when otherwise medically appropriate.** Clearly, locally constrained resources may be a factor in such decision making.

3. Infection prevention and disinfection in imaging departments

The novel COVID-19 is highly contagious and is believed to transmit mostly through respiratory droplets, but there is uncertainty as to whether the virus can be transmitted by touching a surface or from an item that is contaminated.⁷

The recommendations are ¹ (*Consult Figures 1 and 2*)

- Implementation of standardized operating procedure for radiological imaging and procedures for patient with known or suspected COVID-19 exposure.
- Performance of imaging at location with less foot traffic and with fewer critically ill patients. When possible portable imaging and/or ultrasound is preferred.
- Standardized disinfection protocol for decontaminating imaging rooms, especially CT-scanner, after caring **for all patients**. In addition to environmental cleaning and decontamination of rooms occupied by a patient with suspected or known COVID-19 infection, it is recommended that proper protective equipment be worn. The use of N95 mask is recommended (in cases where droplets prevention may not be efficient). It is also necessary that the airflow within fixed radiography or CT scanner rooms should be considered before imaging the next patient. [Ventilation is an important consideration for the control of airborne transmission in health care facilities](#).⁸ Depending on the air exchange rates, rooms may need to be unavailable for approximately 1 hour after imaging infected patients; air circulation rooms can be tested in advance to determine this.²
- Appropriate use of personal protective equipment (PPE) when managing COVID-19 patients is required.

- Remote reading should be preferred whenever possible.
- The waiting room and reading should be adapted to preserve social distancing and cleaned on a regular basis.
- Droplet prevention is critical (no food and drink in disposable containers).

Figure 1

(From ref 7: *J Am Coll Radiol.* 2020 Feb 19. pii: S1546-1440(20)30150-21440)

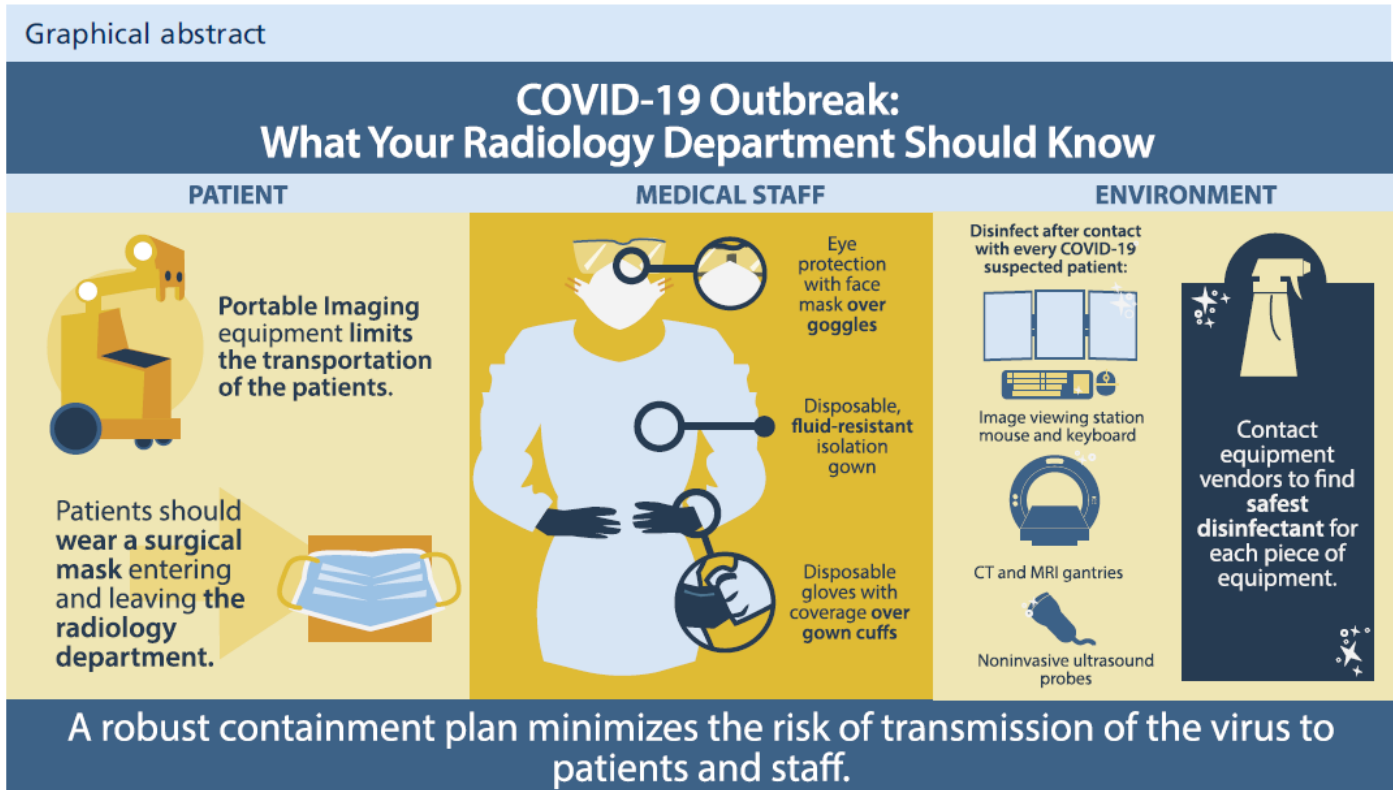
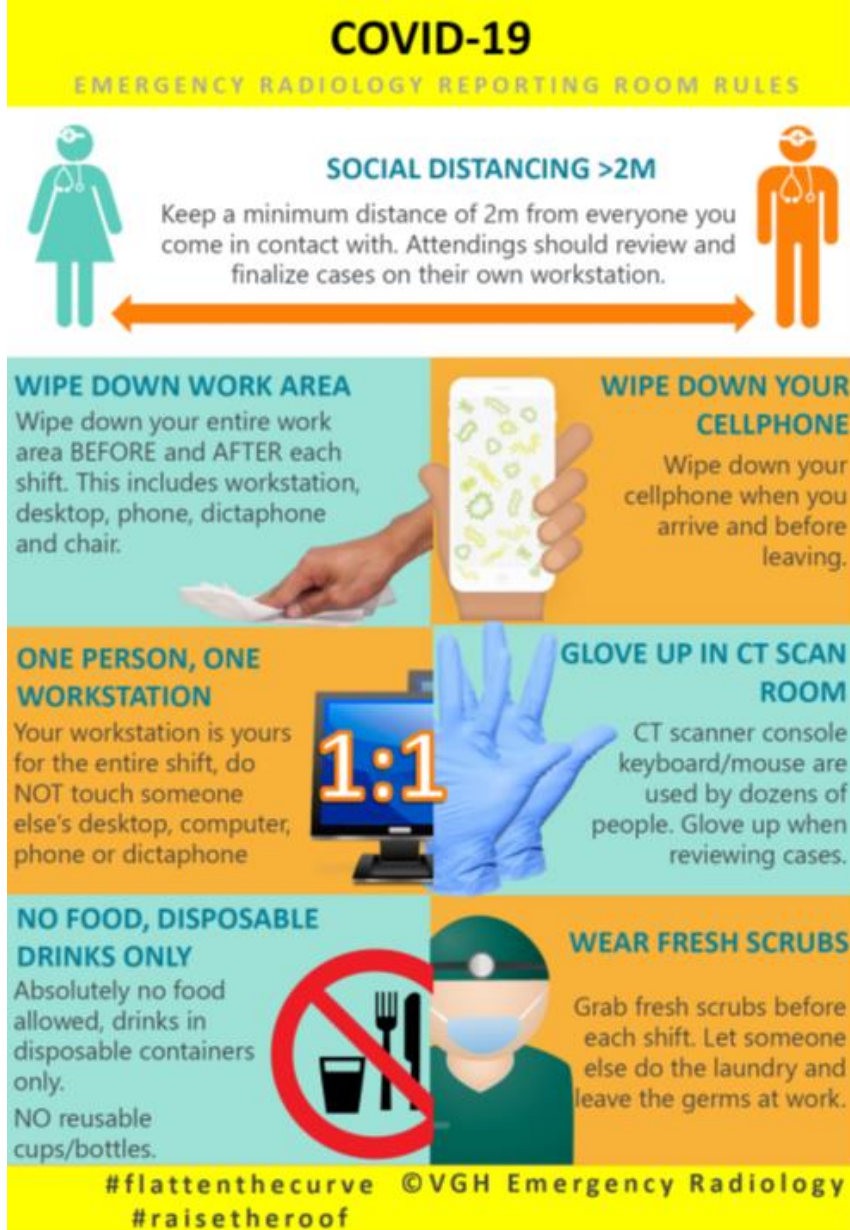

Figure 2

(Infographic provided courtesy of Vancouver General Hospital's Emergency Department)



4. Prioritization of imaging examination

The imaging department should follow the principle of social distancing required by local authorities and minimize non urgent, elective diagnostic or interventional imaging.

- Critical and Non-Critical screening for breast imaging should be postponed. The Canadian Society of Breast Imaging and CAR **recommends that all average risk and high-risk screening mammography, ultrasound and breast MRI be discontinued temporarily (6-8 weeks) with immediate effect.**

- Elective and non-urgent elective imaging examinations should be avoided during the pandemic.
- Particular attention should be given to immunocompromised patients who are more susceptible to develop severe form of the disease.

Summary

The recommendations provided are based on preliminary information that has been gathered from available literature and scientific and medical societies involved in the management of this outbreak. These recommendations can become obsolete if and when more evidence is available in the future. The CAR will continue to update these recommendations when new information becomes available. We believe this exercise is useful to help our members in guiding their decision making. We are facing challenging times and must deliver the best care to our patients, while protecting our colleagues and all the staff involved in patient care. We also need to collect all relevant information from you to improve our policies. Do not hesitate to share information provided by your institution, provincial association and based on your own experience. Working together and exchanging information can save lives and keep everyone safe.

References

1. Mossa-Basha M, Meltzer CC, Kim DC, Tuite MJ, Kolli KP, Tan BS. Radiology Department Preparedness for COVID-19: Radiology Scientific Expert Panel. *Radiology* 2020:200988.
2. ACR Recommendations for the use of Chest Radiography and Computed Tomography (CT) for Suspected COVID-19 Infection. 2020. 2020, at <https://www.acr.org/Advocacy-and-Economics/ACR-Position-Statements/Recommendations-for-Chest-Radiography-and-CT-for-Suspected-COVID19-Infection>.)
3. Canadian Society of Thoracic Radiology and the Canadian Association of Radiologists' Statement on COVID -19. Canadian Association of Radiologist and Canadian Society of Thoracic Imaging, 2020. at <https://car.ca/cstr/>.)
4. Patlas M. COVID-19: What Can We Learn From Stories From the Trenches? *Can Assoc Radiol J* 2020.
5. Dai WC, Zhang HW, Yu J, et al. CT Imaging and Differential Diagnosis of COVID-19. *Can Assoc Radiol J* 2020:846537120913033.
6. Bai HX, Hsieh B, Xiong Z, et al. Performance of radiologists in differentiating COVID-19 from viral pneumonia on chest CT. *Radiology* 2020:200823.
7. Kooraki S, Hosseiny M, Myers L, Gholamrezaezhad A. Coronavirus (COVID-19) Outbreak: What the Department of Radiology Should Know. *J Am Coll Radiol* 2020.
8. Airborne Viral diseases. Center for Disease Control (CDC), 2020. at <https://www.cdc.gov/infectioncontrol/guidelines/environmental/background/air.html#c2c>.)
9. Canadian Society of Breast Imaging and Canadian Association of Radiologists Joint Position Statement on COVID-19. 2020.at https://csbi.ca/wp-content/uploads/2020/03/Covid-19-statement-CSBI_CAR-1.pdf