Imaging Approach to Cerebral Venous Thrombosis

Adam Dmytriw[1,2], Colin Poon[3], Eugene Yu[1], Reza Forghani[2]

2015 Joint Congress on Medical Imaging and Radiation Sciences

Montreal, Quebec
May 28- 30, 2015

1. Department of Medical Imaging , Faculty of Medicine, University of Toronto
2. Department of Diagnostic Radiology, Faculty of Medicine, McGill University
3. Department of Diagnostic Radiology ,Yale Medical School

Disclosures

- No author has any relevant disclosures.

Introduction

- Cerebral venous thrombosis (CVT) is an uncommon form of stroke that is frequently underdiagnosed.

- Diagnosis of CVT is challenging because of the diversity of underlying risk factors, variable clinical presentation, and non-specific imaging findings on initial routine head CT.

Importance

- Prompt diagnosis is important since it can lead to effective treatment. Delayed diagnosis can be associated with high morbidity and mortality.
- Clinical presentation is often nonspecific. Common symptoms and signs include headache, papilledema, seizures, focal neurological deficits and mental status change.
  - Acute (< 2 days) in 30%, subacute (2 days to 1 month) in 50%, chronic (> 1 month) in 20%
  - CVT should be excluded in patients considered for the diagnosis of idiopathic intracranial hypertension because of overlapping clinical presentation

Cerebral Venous Anatomy

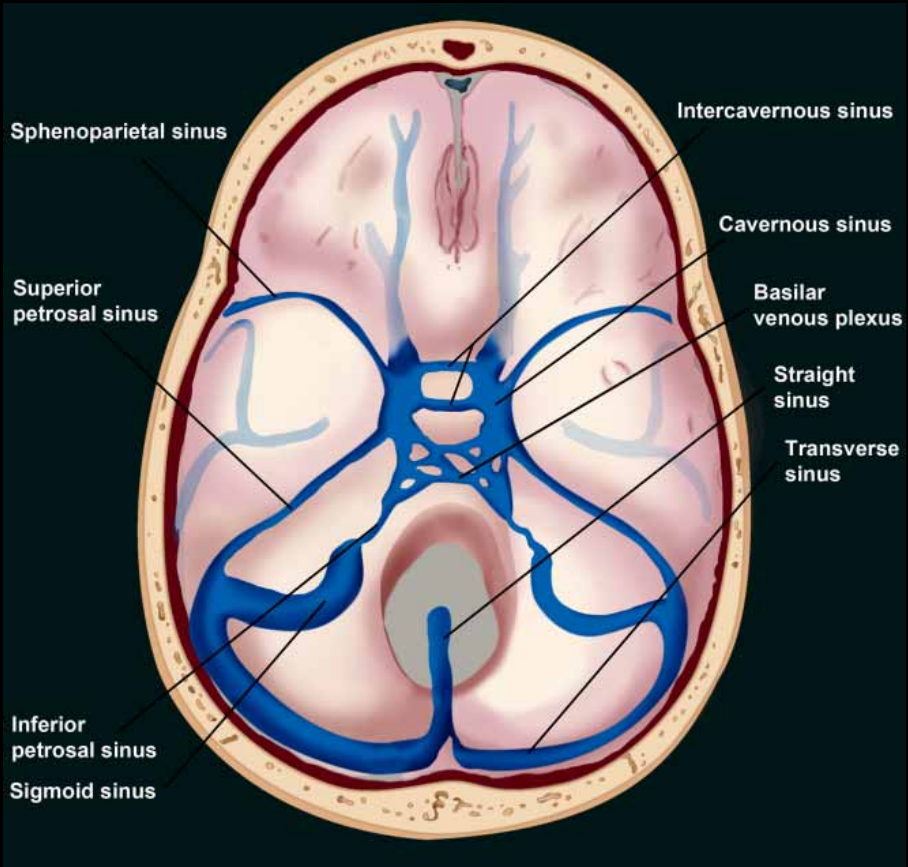

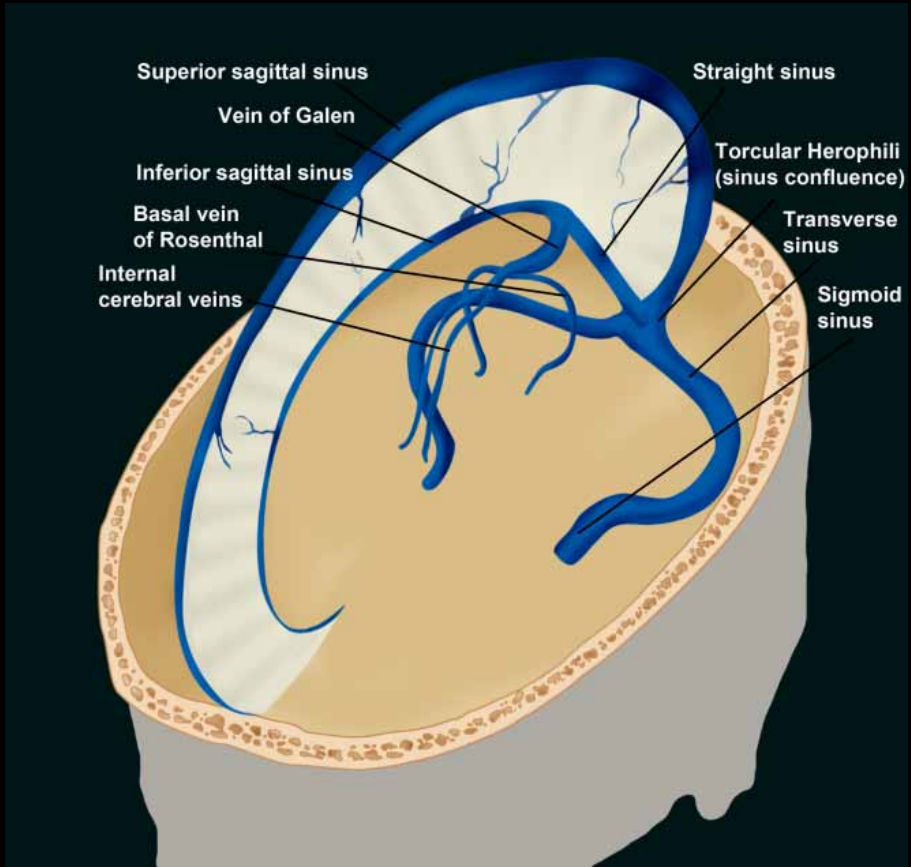

Axial and oblique illustrations demonstrate the major dural venous sinuses and deep cerebral veins.
It is important to be familiar with the major routes of drainage and anatomic variations such as differences in size of sinuses between the left and right sides for accurate interpretation of CT or MR venography.

Diagnostic Imaging Approach to CVT

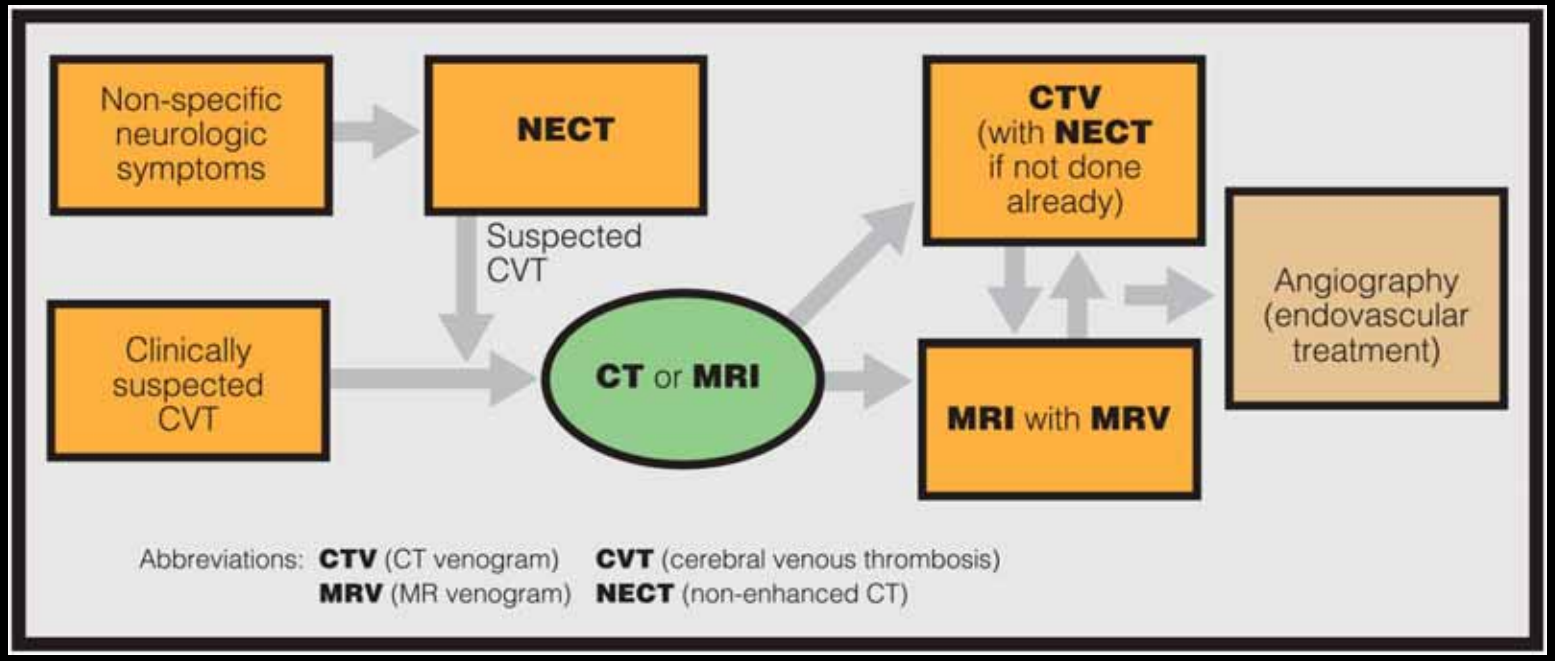

Imaging algorithm for work-up of CVT. Neurovascular imaging may be performed immediately if there is strong clinical suspicion for CVT or alternatively after suspicious findings on routine non-enhanced head CT (NECT).

The findings on CT and MRI partly complement one another and in complex cases both may be performed for optimal diagnostic evaluation.

CT and MRI Findings

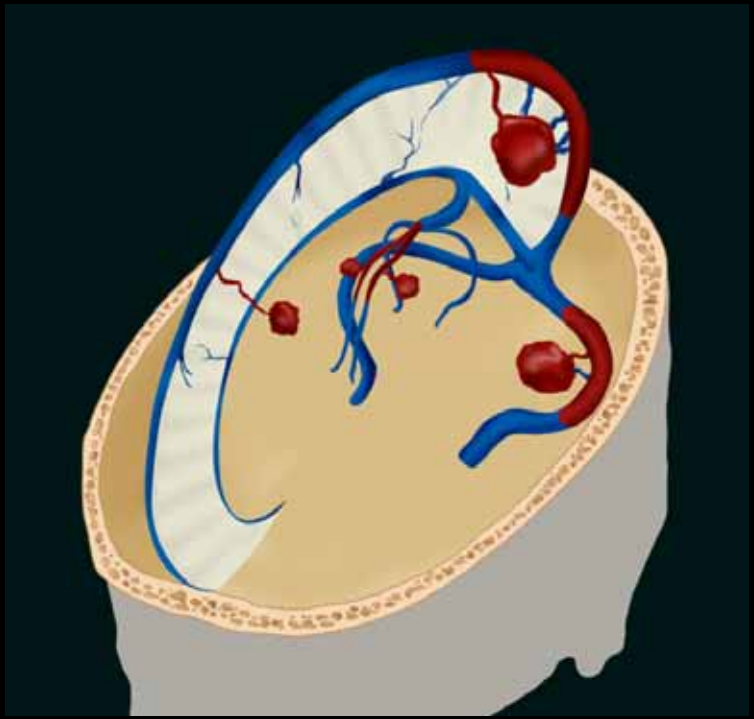

Direct Signs	Indirect Signs
• Dense triangle sign (clot in sinus on NECT) • Cord sign (thrombosed cerebral vein on NECT). MRI equivalent: thrombosed vein seen on gradient or susceptibility images or rarely other sequences • Empty delta sign (clot as filling defect within the sinuses on CTV/MRV) • Replacement of normal dark flow void with clot on MRI	• Cerebral edema with elevated or mixed diffusion characteristics • Cortical hemorrhagic infarction • Subarachnoid hemorrhage • Rarely subdural hemorrhage

The site and extent of parenchymal lesions secondary to CVT depends on the vein or veins affected, extent of clot, and presence of collateral drainage pathways. The presence of hemorrhage or vasogenic edema in locations shown on the illustration, near a major venous sinus or deep cerebral vein, should raise suspicion for CVT.

Indirect Signs

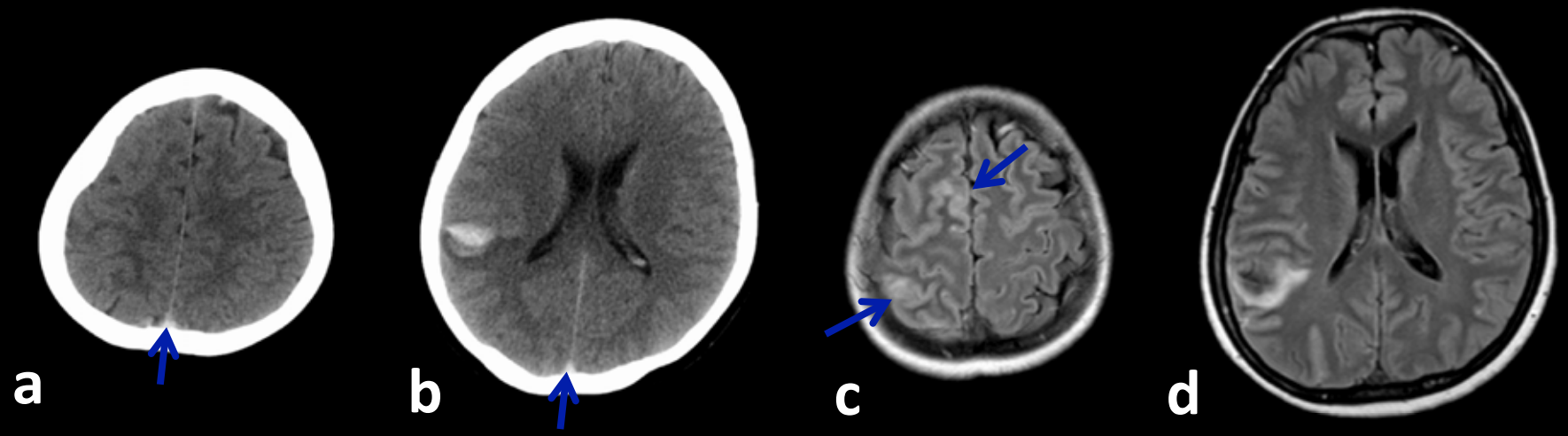

Parenchymal abnormalities in CVT on CT and MRI obtained on the same day from a 38 yo female patient. The NECT images (a, b) demonstrate lobar hemorrhage in the right parietal lobe extending to junction with temporal lobe with a dense SSS (arrow) highly suspicious for CVT. MRI has much greater sensitivity for parenchymal abnormalities, and the FLAIR images (c, d) demonstrate additional mixed signal abnormalities secondary to vasogenic edema (arrows) not clearly visible on the CT. These are in non-contiguous locations involving multiple vascular territories and do not conform to any typical large arterial territory infarct. This combination of findings consisting of a mix of hemorrhage and vasogenic edema in this pattern is highly suspicious for CVT.

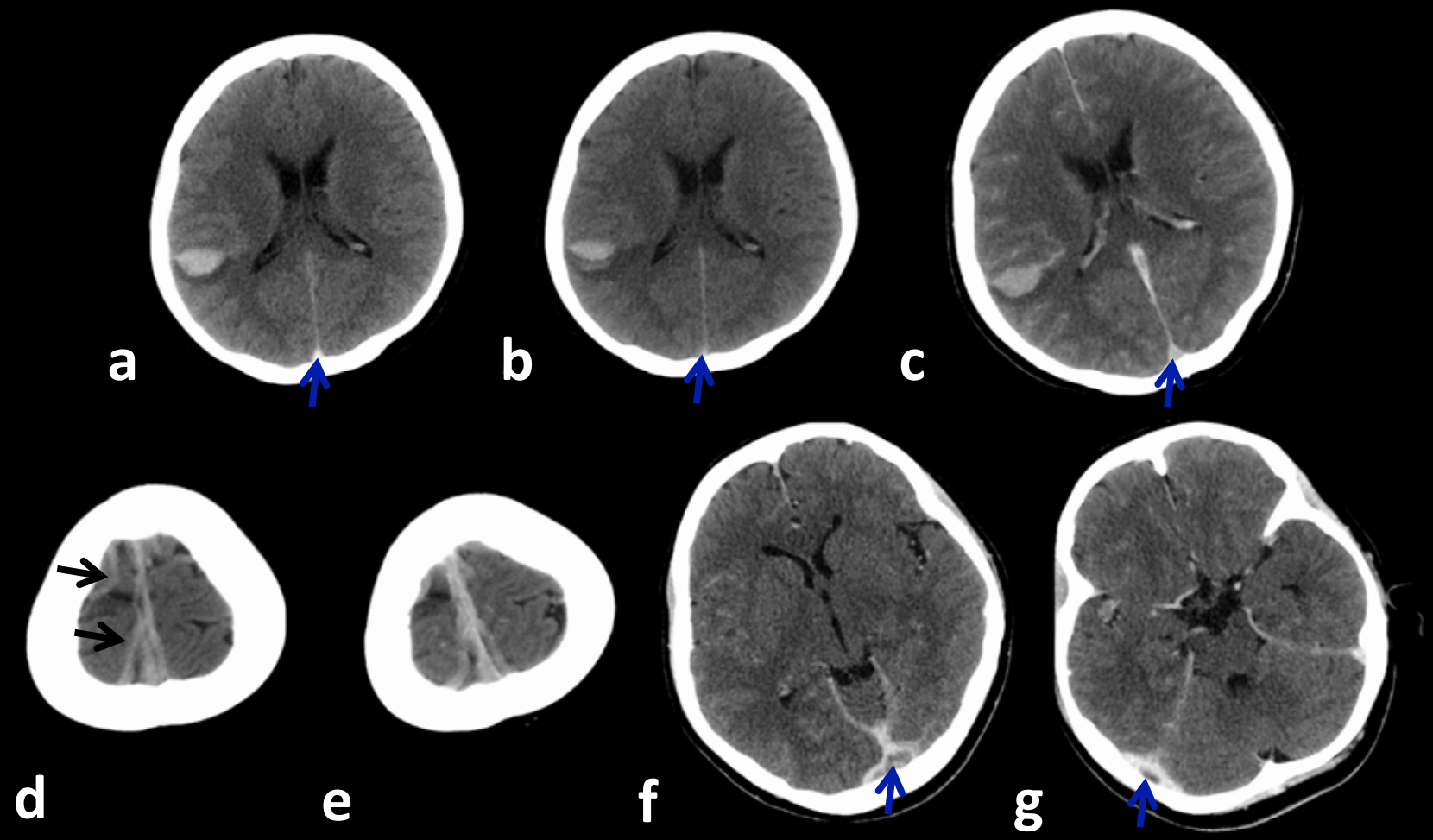

Different CT appearances of clot and potential pitfalls on CTV. NECT images from a patient with CVT demonstrate very high density clot on day 1 (a; arrow) but less dense appearance of clot on day 6 in the same patient undergoing treatment (b; arrow). Based on the venogram alone, the acute clot mimics normally opacified sinus (c; arrow). Axial images obtained without (d) and with contrast (e; CTV) at the vertex from a patient with extensive CVT are shown, and are almost indistinguishable, again demonstrating how dense acute clot
may mimic opacified sinus. Note the dense thrombosed cortical veins on the NECT (black arrows; cord sign). Two additional CT venogram images (f, g) are shown demonstrating the somewhat less dense appearance of subacute clot (blue arrow; f) enabling clear distinction from contrast at the level of torcular (equivalent of empty

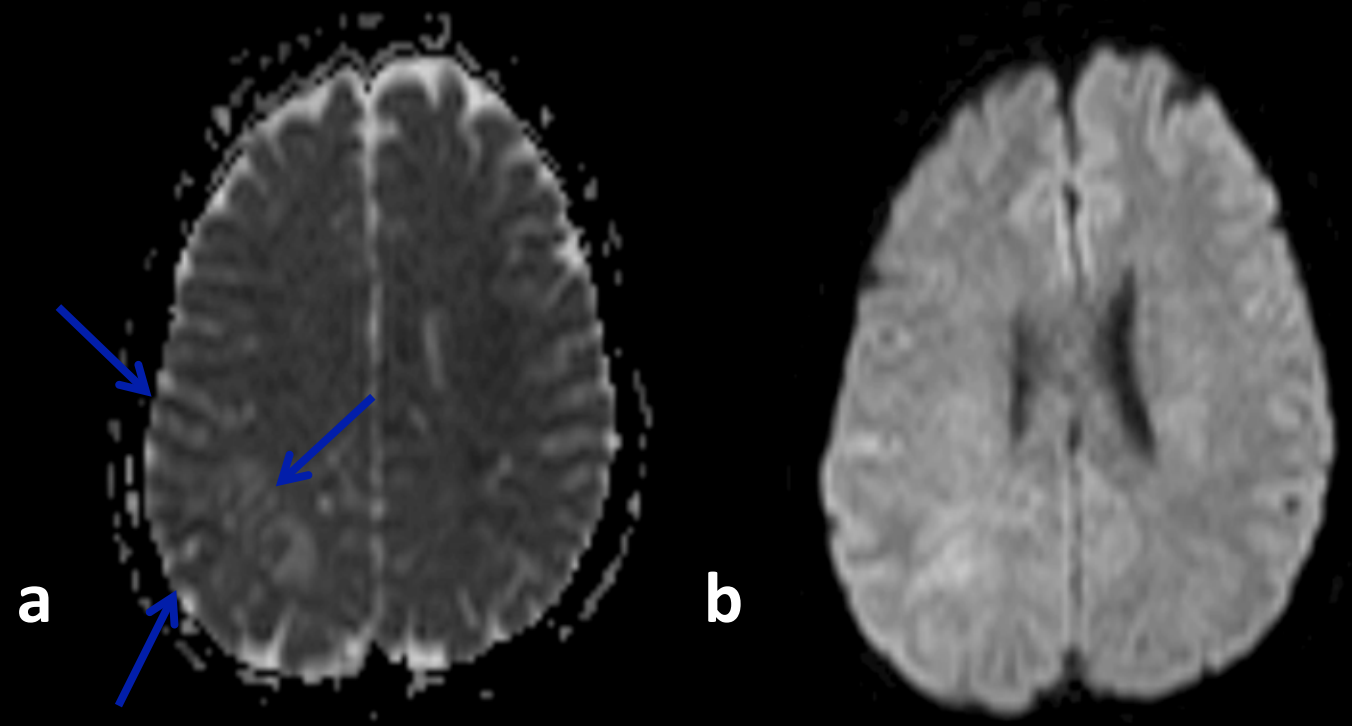

Axial ADC (a) and DWI (b) maps demonstrate mixed diffusion signal in the right parietal lobe.
There is very mild cortical diffusion restriction (arrows) but elevated diffusion in adjacent subcortical matter.
This pattern is highly atypical of arterial infarction and instead consistent with vasogenic edema syndrome as seen in CVT (among a long list of other differentials).

Direct Signs

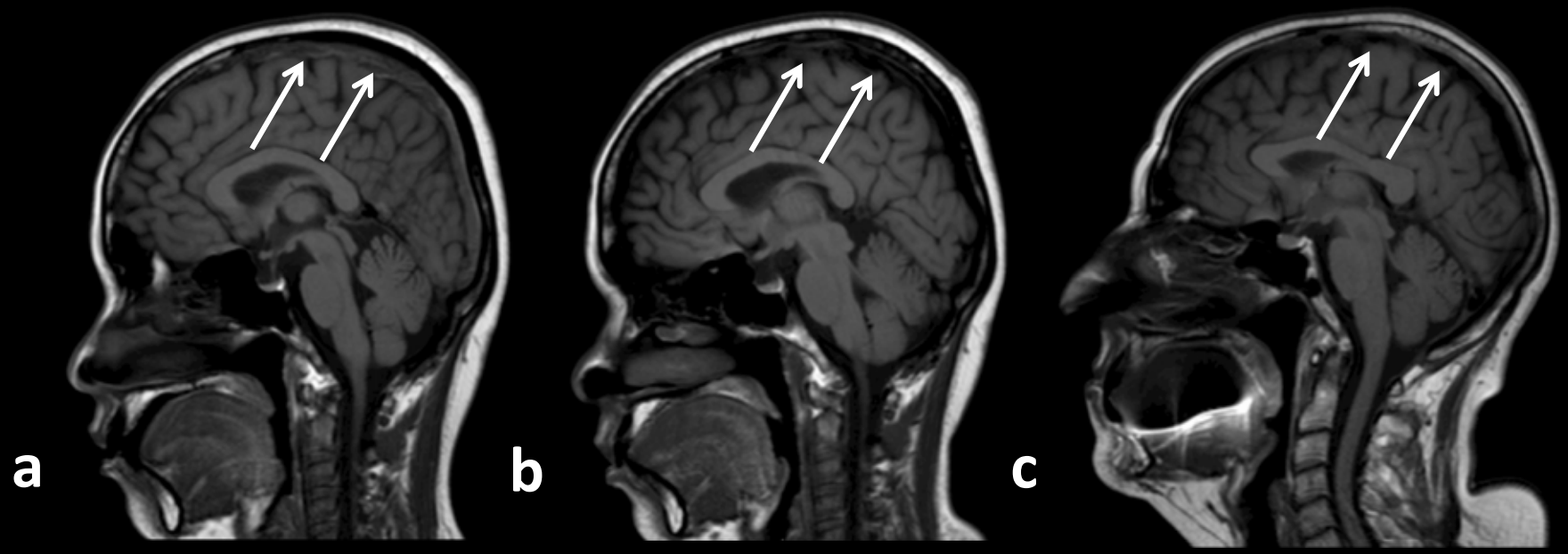

Midline sagittal T1w image (a) demonstrates extensive clot replacing the normal signal void in the SSS (arrow). Follow-up 4 months after treatment (b) and comparison view from a normal patient (c) demonstrate normal flow void of SSS.

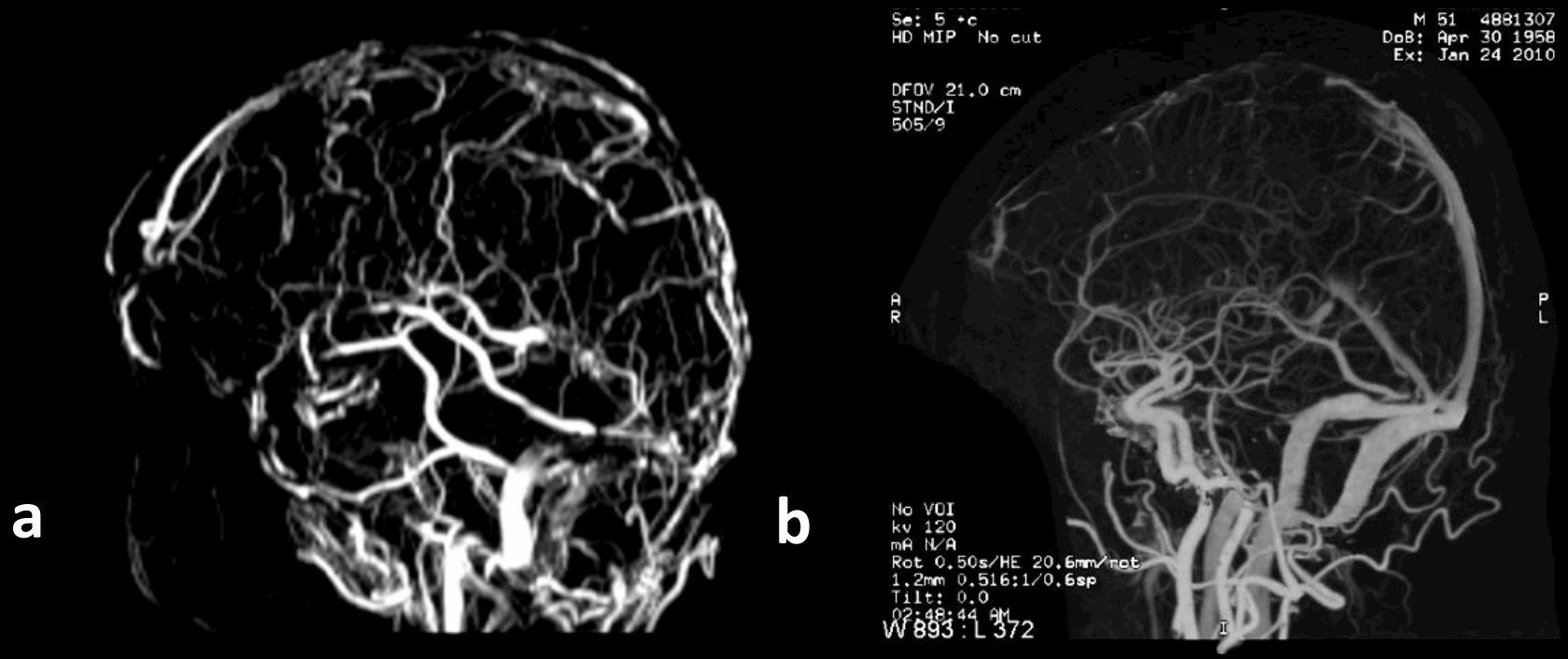

2D TOF MRV (a) and CTV (b) demonstrating extensive superior sagittal sinus thrombosis in 2 different patients with CVT.

Troubleshooting

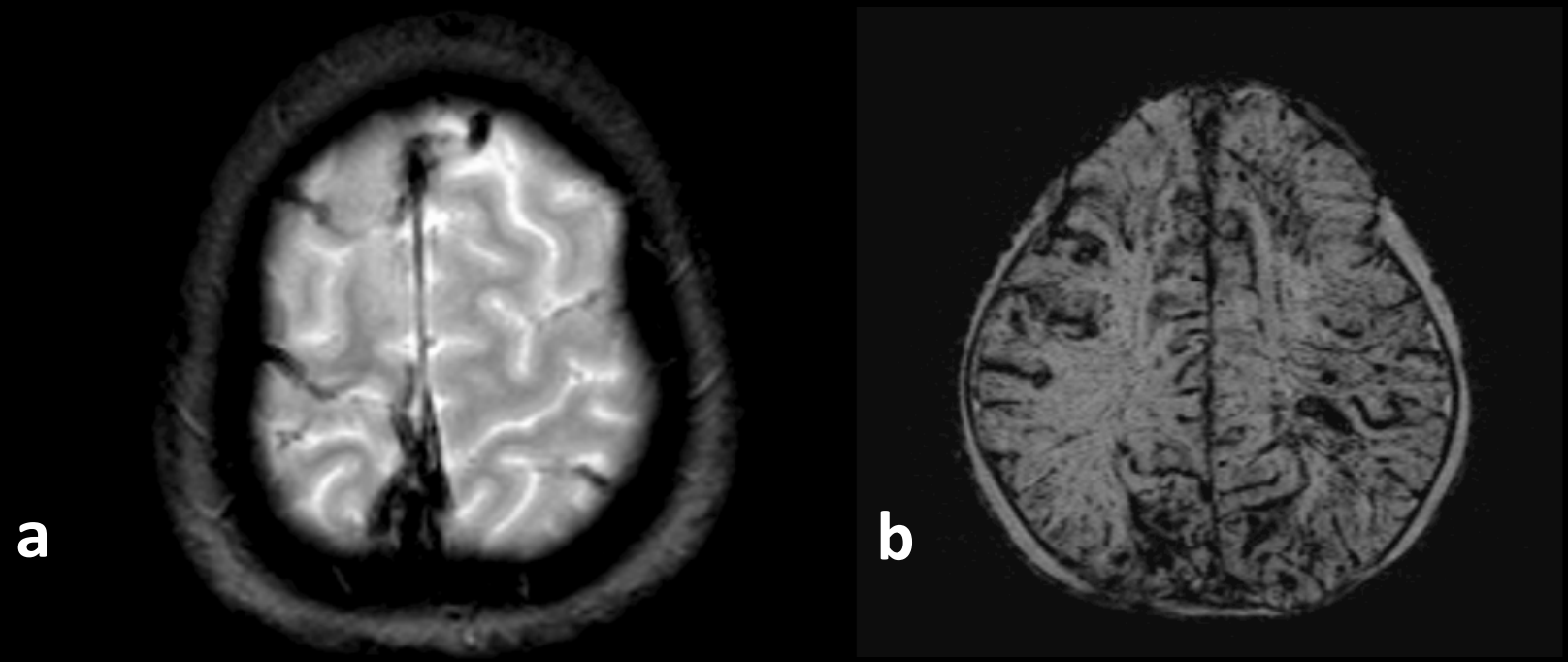

Gradient recalled echo (a) or susceptibility weighted images (b) can be very useful adjunctive sequences for demonstrating clots within dural venous sinuses or cortical veins. In (a), there is blooming artifact from clot within the SSS and cortical veins. In (b), there is extensive SSS and cortical vein thrombosis mixed with subarachnoid hemorrhage.

Comparison of CTV and MRV

	Pros	Cons
MRI/ MRV	• No radiation risk • Higher sensitivity for small parenchymal lesions • MRV can be performed in patients with severe renal failure if done without contrast (2D TOF) • Low rate of adverse contrast reactions	• Contraindicated in patients with ferromagnetic devices, mostly pacemakers • More prone to flow-related image artifacts; may result in higher false positive rate but contrast enhanced MRV may overcome this limitation • More prone to motion artifact
CTV	• Rapid image acquisition • Less prone to motion artifact • More suitable for unstable patients • More widely accessible • Better depiction of small vessels • Generally costs less than MRI	• Dense acute clot may mimic opacified sinus resulting in false negative • Higher incidence of adverse reactions to Iodinated contrasts; risk of contrast induced nephropathy • Potentially limited visualization of skull base structures in 3D display • Results in exposure to ionizing radiation

Important Pitfalls

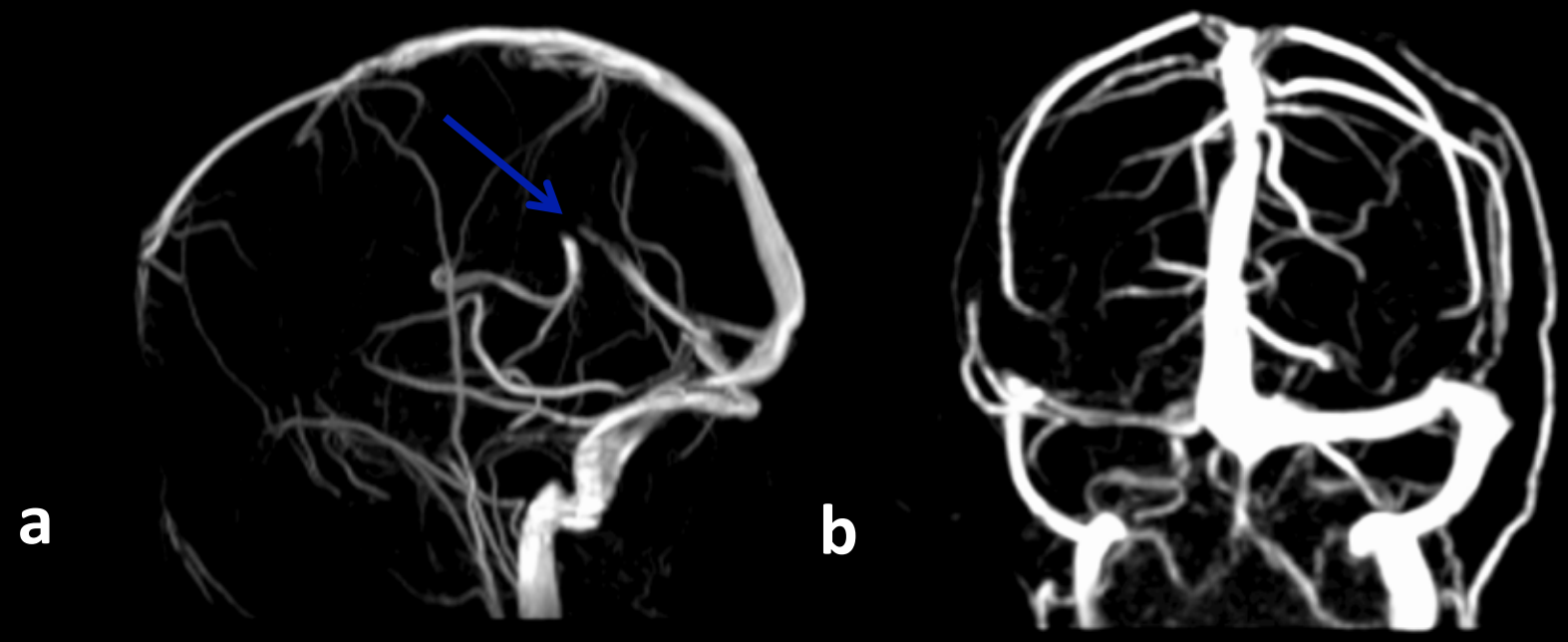

2D TOF MRV (MIPs). (a) There is frequently signal drop-out at the junction of the straight sinus and vein of Galen which should not be mistaken for thrombus (arrow). (b) Hypoplastic right transverse sinus, representing an anatomic variant.

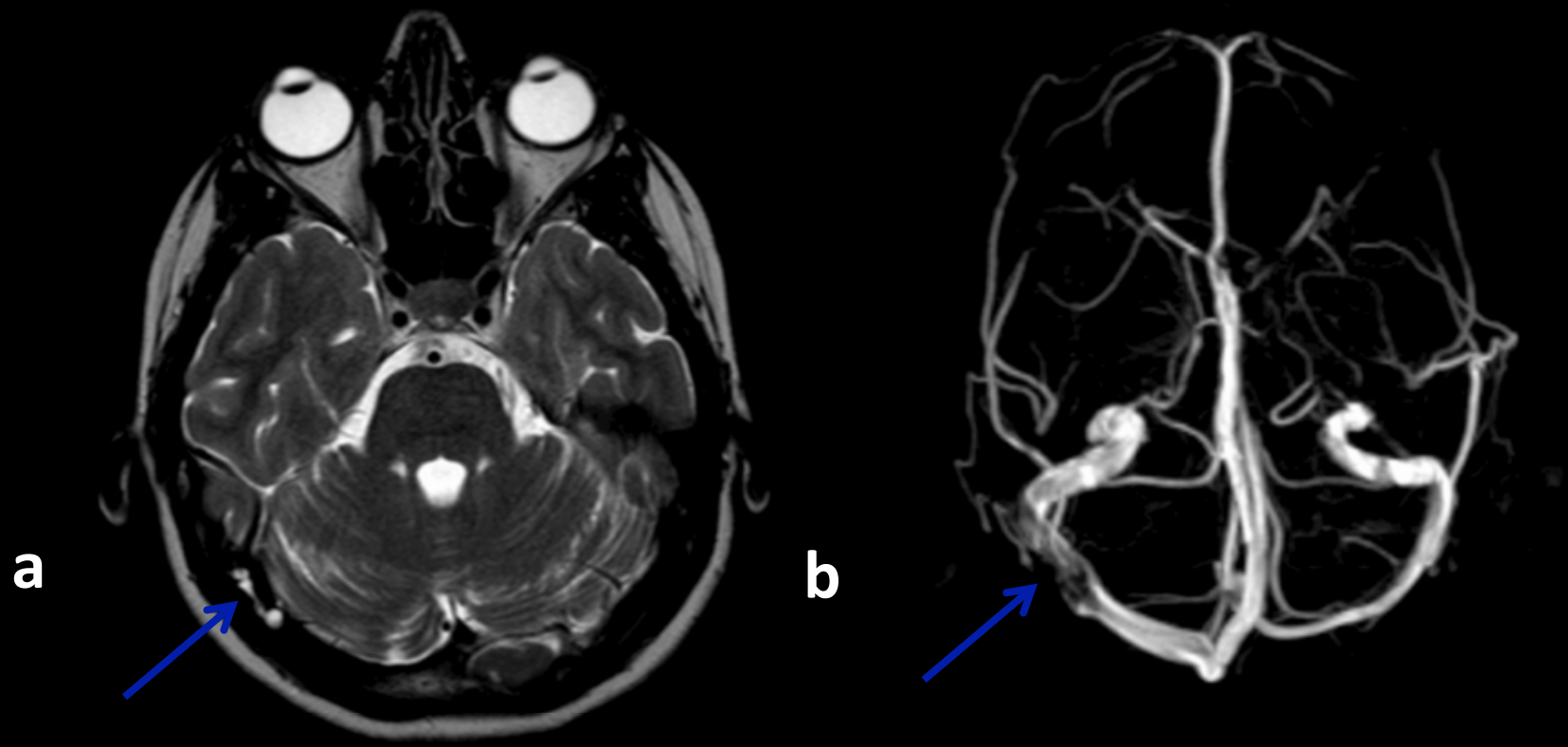

Arachnoid granulations should not be mistaken for thrombus. Axial T2w MRI image (a) and MIP image from a 2D TOF MRV (b) demonstrate typical arachnoid granulations in the right transverse sinus (arrow).

Pitfall Summary

Modality	Pitfalls
NECT	• Normal hyperdensity in patent dural sinuses may mimic thrombosis, especially in children or patients with hemoconcentration.
CTV	• Dense acute clot may mimic sinus opacification on CTV. CTV may have greater sensitivity for detection of subacute or chronic clot.
Conventional MRI	• Variation in intensity of thrombus on different sequences depending on age of clot. • Acute and early subacute hemorrhage (clot) appearing hypointense on T2 weighted images, may mimic flow void seen in patent venous sinus.
MRV	• Signal loss due to in-plane or complex flow, particularly on unenhanced 2D TOF MRV. • Chronic thrombosis with incomplete recanalization may have marked contrast enhancement and mimic a patent sinus on post-gadolinium images.
All Modalities	• Hypoplastic or aplastic sinus mimicking CVT. • Arachnoid granulation, intrasinus septa, or fenestrated dural sinus mimicking thrombus. • Tumor invasion or compression of dural sinuses mimicking bland CVT (there is increased risk of bland thrombus in patients with invaded or compressed sinuses).

Endovascular Management

- Unfractionated or low molecular weight heparin are the mainstay of treatment for CVT.
- In patients who worsen despite its administration, direct thrombolysis or thrombectomy may be beneficial in carefully selected cases.
- Evolving mechanical techniques including rheolytic, stent-retriever and suction extraction are safe and effective in restoring vessel patency and several case series report successful reversal of clinical deficit.
- Mechanical intervention may confer a smaller bleeding risk than anticoagulation or direct thrombolysis.

Interventional Case

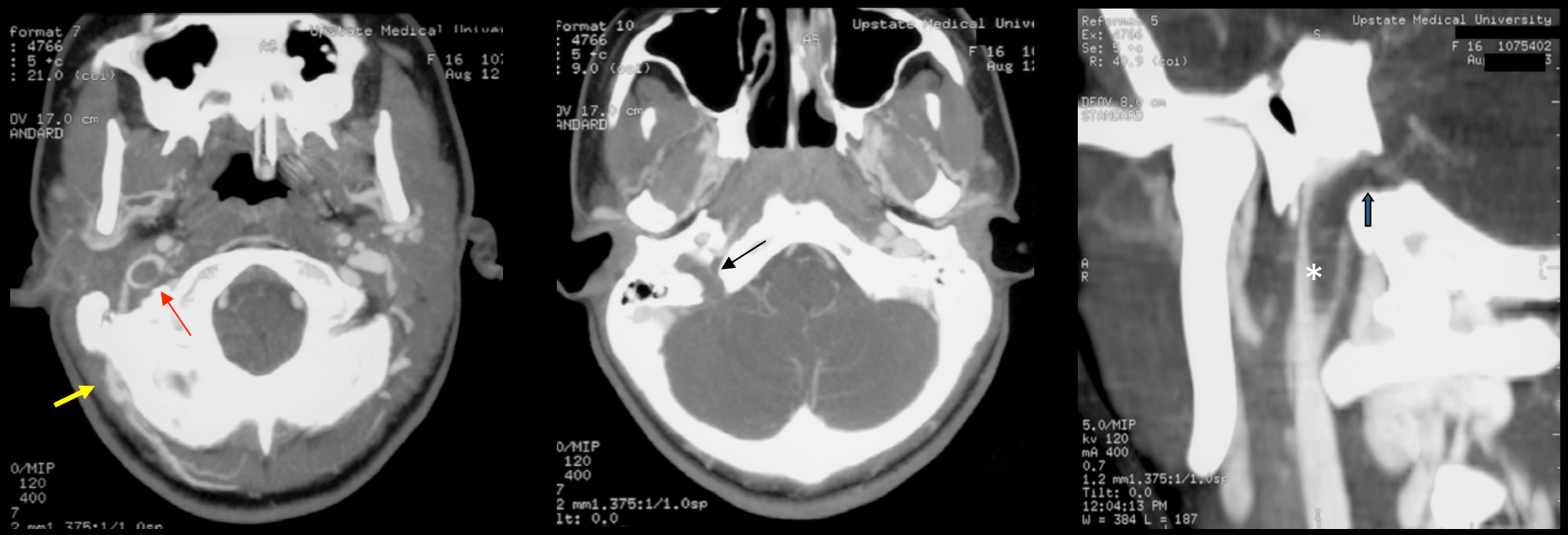

a b c

Red arrow and red asterisk = right internal jugular vein. Black arrow = sigmoid sinus. Blue arrow = torcular Herophili. (A and B) Source images of CTV. Thrombus in IJV and sigmoid sinus was seen as filling defect. Note the collateral veins (yellow arrow) arising from the right IJV. (C) Sagittal planar reconstruction of CTV showed thrombus extending from right IJV into the sigmoid sinus, correlating well with conventional venography (next slide).

Case Continued

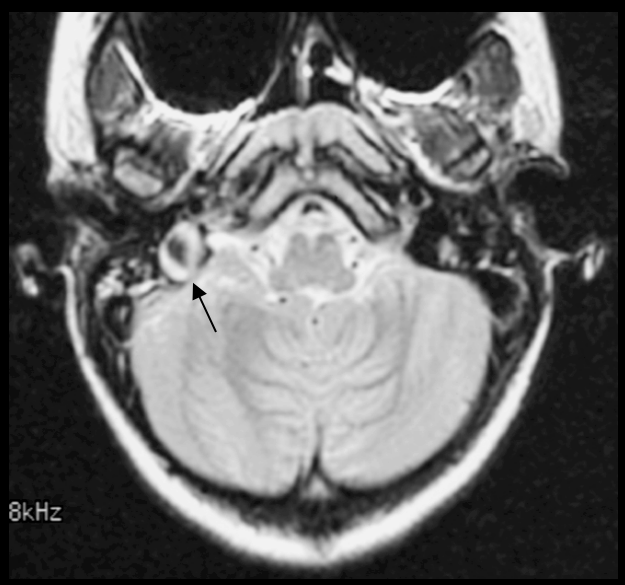

d

e

f

(D) T1W MR image showed sigmoid sinus thrombosis, as loss of flow void. (E) Conventional venogram showed thrombus as filling defects. Note the collateral veins at the region of the right IJV, also shown by CTV. (F) Venography after suction thrombectomy showed improved patency in the right IVJ and lateral sinus.

Conclusion

- Timely diagnosis of CVT requires a high index of suspicion. Recognition of patterns of parenchymal abnormalities and hemorrhage compared with other diseases and arterial infarcts is key for early recognition and work-up of CVT.

- Both CTV and MRI with MRV are acceptable methods for work-up and diagnosis of suspected CVT. The techniques are also complementary and may be combined for optimal evaluation in complex or equivocal cases.

- MRI enables better delineation of parenchymal abnormalities compared to CT. Familiarity with signs of CVT on conventional sequences is key for optimal evaluation and to avoid pitfalls that may be encountered by relying on the angiographic sequences alone.