Canadian Society of Thoracic Radiology

Canadian Association of Radiologists
L'Association canadienne des radiologistes

The Canadian Society of Thoracic Radiology (CSTR) and Canadian Association of Radiologists (CAR) Consensus Statement Regarding Chest Imaging in Suspected and Confirmed COVID-19

April 17, 2020

Carole Dennie, Cameron Hague, Robert S. Lim, Daria Manos, Brett F. Memauri, Elsie T. Nguyen, Jana Taylor

Approved by CSTR Executive and CAR Board of Directors – April 17, 2020

Introduction

On March 11, 2020, the World Health Organization (WHO) declared COVID-19 a global pandemic. At the time of writing, there were 28,893 cases of COVID-19 in Canada with 2,056,055 worldwide. An unprecedented amount of effort has been put into learning about this disease across the globe with a focus on slowing its spread, improving its detection, finding treatment and developing a vaccine. On March 30, 2020, the Canadian Society of Thoracic Radiology (CSTR) posted its first position statement regarding thoracic imaging during the pandemic. As a result of ongoing data collection and research, we follow this up with an updated consensus statement which is based on the expert opinion of 6 thoracic radiologists from across the country and 1 thoracic imaging fellow with input from the Canadian Association of Radiologists (CAR) Executive Board. The focus of this update is foremost on chest imaging rather than imaging logistics and infection control during the pandemic. We have tackled this update by addressing frequently asked questions in the radiology community, primarily the role of chest radiography, chest CT and lung ultrasound.

The consensus statement covers the following topics:

1. When is chest radiography appropriate in patients with suspected or confirmed COVID-19 infection?
2. When is chest CT appropriate in patients with suspected or confirmed COVID-19 infection?
3. How should a radiologist deal with incidental findings of COVID-19 on CT chest done for other indications?
4. Should lung ultrasound (LUS) be used to diagnose or exclude COVID-19 pneumonia?

Acknowledgment

The CSTR would like to acknowledge its Executive and the CAR Board of Directors who provided the direction for these guidelines. CSTR Executive members: Carole Dennie, Cameron Hague, Robert S. Lim, Daria Manos, Brett F. Memauri, Elsie T. Nguyen, Jana Taylor.

Resources:

- Canadian Society of Thoracic Radiology/CAR Joint Position Statement on COVID-19 – March 30, 2020
- Additional COVID-19 information and resources - https://car.ca/covid-19/

When is chest radiography appropriate in patients with suspected or confirmed COVID-19 infection?

Chest radiography is often the initial imaging modality of choice for clinicians who are evaluating patients with known or suspected COVID-19 pneumonia. However, chest radiographs are insensitive for the diagnosis of COVID-19 pneumonia and a negative chest x-ray does not rule out COVID-19 infection[1]. The reverse transcriptase polymerase chain reaction (RT-PCR) assay remains the gold standard for diagnosis. Chest radiography should not be used to exclude COVID-19 infection. It lacks sensitivity (69%) and is often normal early in the disease[1, 2]. Even when present, the imaging features of COVID-19 pneumonia are nonspecific but when present, increase the pretest probability of COVID-19 infection. The chest x-ray is most useful when an alternative diagnosis is found that completely explains the patient's presenting symptoms such as, but not limited, to pneumothorax, pulmonary edema, large pleural effusions, lung mass or lung collapse. At all times, it is important to limit imaging to those in whom results are expected to change management to avoid the risks of potential virus transmission to healthcare professionals.

Protecting healthcare personnel and reducing the risk of transmission

1. When deemed necessary, chest x-rays should be performed using a portable radiography unit. Digital radiography (DR) is preferred over computed radiography (CR) if available. The use of portable radiography will avoid patient transport into the radiology department thus limiting exposure to healthcare workers and other patients in the imaging department. Portable x-ray machines, detectors and cassettes are also easy to clean and detectors and cassettes can be protected by a plastic cover that can be changed between patients. Portable radiographs can also be obtained through a glass wall, potentially conserving personal protective equipment.
2. If a patient does require an x-ray to be performed in the radiology department, there should ideally be consideration for a pre-assigned room to limit department exposure. After imaging, the room should be appropriately cleaned.

In COVID-19 assessment centers and family physician outpatient clinics:

1. If a family physician is concerned for COVID-19 infection, further evaluation at a dedicated COVID-19 assessment facility and RT-PCR testing are recommended.
2. A chest x-ray is not recommended in individuals presenting with mild symptoms because imaging is often normal [2] and this may be falsely reassuring. Patients should be instructed to stay home, self-isolate and monitor symptoms while awaiting the result of the RT-PCR test.
3. In patients presenting with moderate to severe symptoms, chest radiography, if available may be useful in addition to clinical judgement to determine if there is a need for additional assessment in a hospital setting.

In the Emergency Department (ED) setting:

1. In a patient with concerning symptoms, when the RT-PCR assay is not yet available, a chest radiograph is useful. Although the imaging features of COVID-19 pneumonia are nonspecific, when present, they increase the pretest probability of the patient having the disease. Findings suggestive of an alternative diagnosis (pneumothorax, large pleural effusions, lung mass, etc.) that requires treatment are also extremely useful.
2. Immunocompromised and high-risk individuals are more susceptible to severe infection[3]. High-risk individuals have been identified as having risk factors which include age >65 years, cardiovascular disease, diabetes, chronic respiratory disease and hypertension[4]. While a chest x-ray may be of limited value for COVID-19 diagnosis, an abnormal result may be a useful adjunct for clinicians in their management decisions. An imaging algorithm for this clinical scenario is outlined in Figure 1.
3. If a patient with an initial negative RT-PCR result returns to the ED with worsening symptoms, a chest x-ray may be useful to detect COVID-19 pneumonia and complications. As the number of days increases from initial symptom onset, the chest radiograph has an increased likelihood of being abnormal[1, 5]. A negative chest x-ray still does not exclude the possibility of COVID-19 infection and repeat RT-PCR testing is still required. An imaging algorithm for this clinical scenario is outlined in Figure 2.

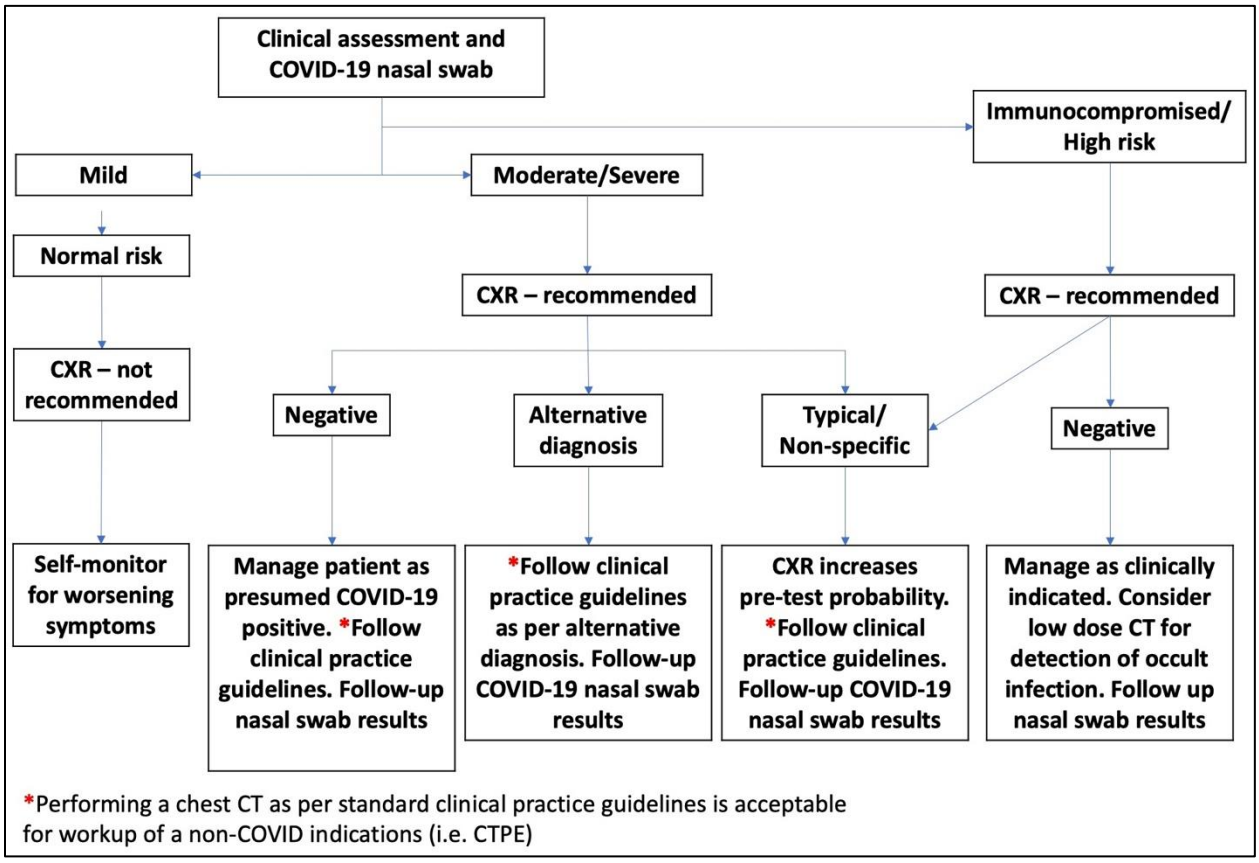

Figure 1 – COVID-19 Chest imaging algorithm for initial presentation

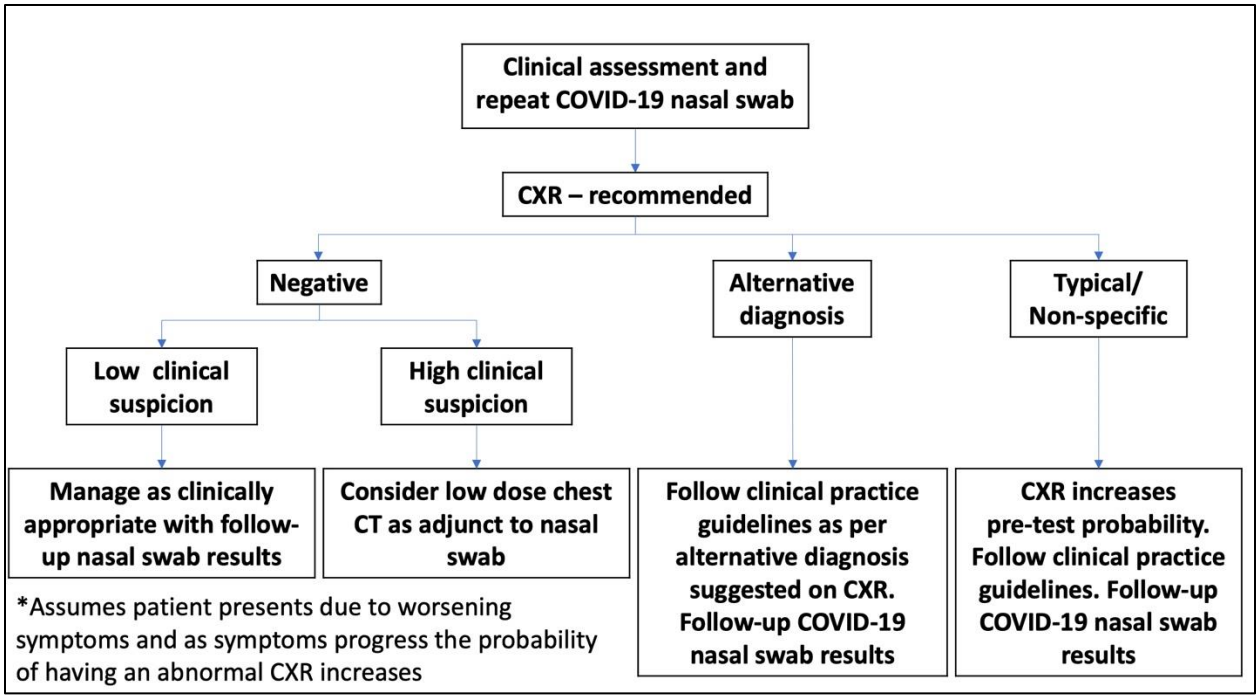

Figure 2 – COVID-19 Imaging algorithm for repeat presentation and initial negative COVID-19 RT-PCR test

In the inpatient setting:

1. Chest x-rays are useful in clinically worsening patients but daily chest x-rays in stable patients are not necessary and may increase the risk of viral transmission[6, 7] to healthcare workers.
2. The role of chest radiography to monitor disease progression is unknown. In systematic reviews of patients with lower respiratory infections and patients in the intensive care unit (ICU), follow-up chest x-rays did not result in a change in management that shortened duration of patient symptoms or reduced the incidence adverse events[7, 8]. In a study of patients with COVID-19 pneumonia in Wuhan, China who had follow-up CTs and PCR, less than half (42%) showed improvement on chest CT prior to converting to a negative PCR [1]. Thus, CT was not helpful in monitoring disease progression. Results could be extrapolated to chest radiography[6].

Recommendations on reporting chest radiographic findings

Adoption of standardized language is recommended by the CSTR. Analogous to standardized reporting of CT, it is felt that this will lessen variability in the interpretation of chest radiographic findings and facilitate correct identification of frequently and infrequently reported imaging features in this clinical context.

Suggested categorization and reporting language

When typical findings[1, 2] are identified on a chest x-ray the term "*typical appearance*" is suggested. In the impression, the following wording could be used: *"In the appropriate clinical setting, the imaging features are considered typical of COVID-19 pneumonia but can also be seen in other types of viral pneumonia such as influenza pneumonia and with a drug reaction or organizing pneumonia".* When non-specific findings[1, 2] are identified, the term "*non-specific appearance*" should be used and the suggested wording in the impression is as follows: *"The imaging features are non-specific and may be attributable to a variety of causes such as infection, including but not exclusive to COVID-19 and inflammatory conditions. It is recommended that further management be based on non-imaging parameters of the presentation".* Finally, if the chest radiograph is normal or non-contributory, the term "*negative for pneumonia*" should be used and the impression should read: *"Negative for pneumonia. Note that a negative CXR does not exclude COVID-19 infection."* The Imaging findings and proposed reporting structure are summarized in Table 1.

Table 1 – Proposed reporting structure for chest radiography in patients with suspected or confirmed COVID-19

Categories	Rationale	CXR Findings[1, 2]	Proposed Reporting Language
Typical appearance (Figure 3)	Presently have a higher specificity for COVID-19 pneumonia	-Bilateral peripheral multifocal opacities or consolidation -Lower lung zone predominant	In the appropriate clinical setting, the imaging features are considered typical of COVID-19 pneumonia but can also be seen in other types of viral pneumonia such as influenza pneumonia and with a drug reaction or organizing pneumonia.
Non-specific appearance (Figure 4)	Not as commonly found in COVID-19 pneumonia	-Unilateral and/or perihilar opacities or consolidation -No zonal predominance or upper lung zone predominant -Cavitation -Kerley B lines with pleural effusion -Lymphadenopathy	The imaging features are non-specific and may be attributable to a variety of causes such as infection, including but not exclusive to COVID-19 and inflammatory conditions. It is recommended that further management be based on non-imaging parameters of the presentation.

Negative for pneumonia	Findings are either absent or non-contributory towards an infectious diagnosis	-Lack any findings to suggest pneumonia	Negative for pneumonia. Note that a negative CXR does not exclude COVID-19 infection.

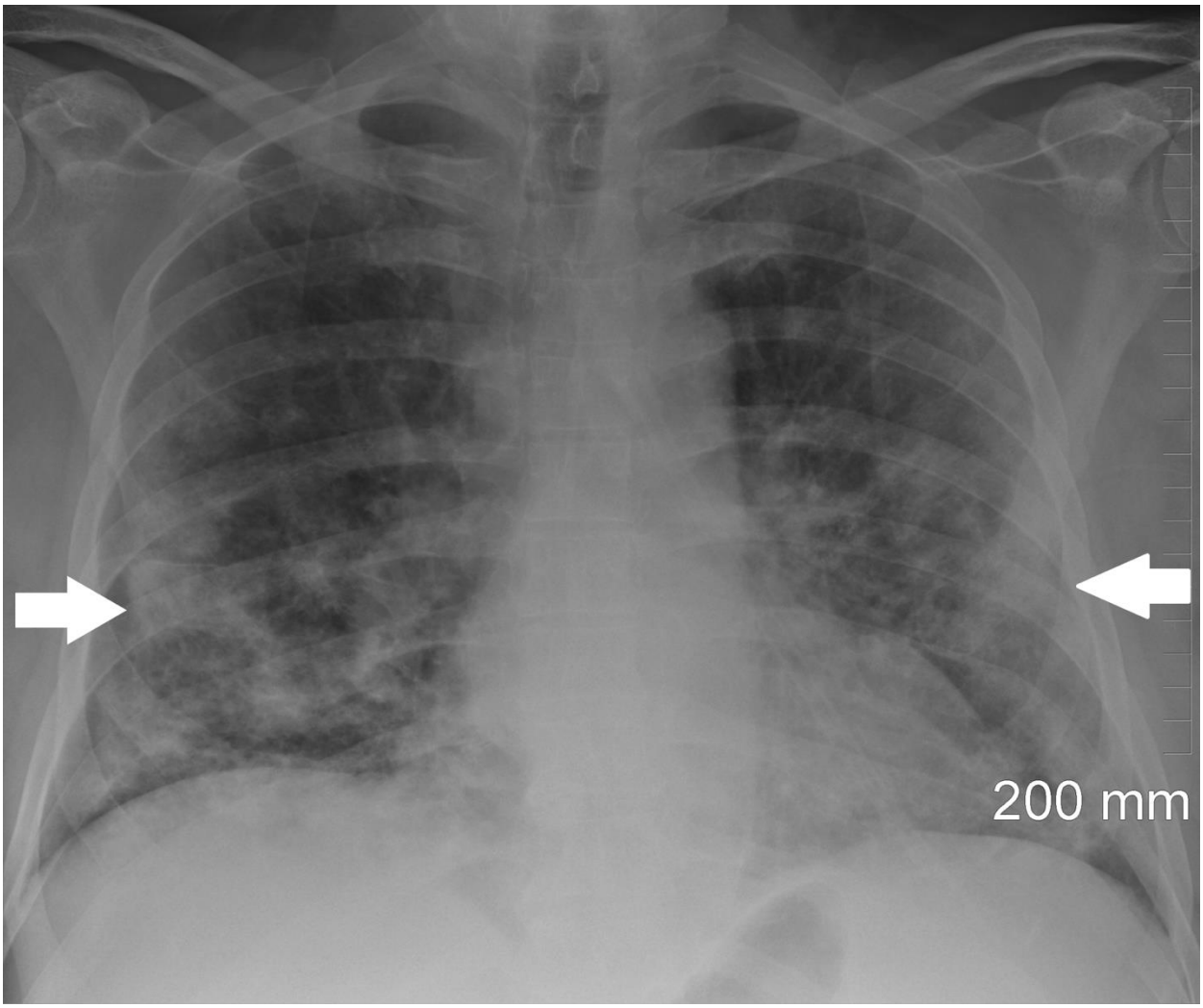

Figure 3 – Chest radiograph depicting "*typical appearance*". This 66-year-old man with chronic lymphocytic leukemia presented to the Emergency Department with a history of fever, worsening shortness of breath, night sweats, myalgia and diarrhea. He had tested positive for coronavirus disease seven days earlier. Chest radiographic findings include lower zone predominant bilateral, peripheral opacities (arrows). There is no pleural fluid.

Figure 4 – Chest radiograph depicting "*non-specific appearance*". This 55-year-old woman with chronic renal insufficiency presented to hospital with a one-week history of cough, shortness of breath, malaise and low-grade fever. RT-PCR was positive for COVID-19. Chest radiographic findings include diffuse bilateral opacities with no zonal predominance.

When is chest CT appropriate in patients with suspected or confirmed COVID-19 infection?

Historically, standard dose CT chest was superior for the detection of subtle ground-glass opacities as compared to low dose technique[9]. With the advent of iterative reconstruction algorithms to reduce the visibility of image noise and maintain image quality, low-dose chest CT is appropriate in the majority of patients[10].

Similar to chest radiography, CT should only be performed if the results are expected to influence patient management. Performance of chest CT requires patient transport to the imaging department and therefore entails careful planning to mitigate the risk of potential

infection of health care workers and other patients. CT should not be used to routinely screen patients for possible COVID-19. The following is a list of potential indications or clinical scenarios for which CT chest may be warranted (Figure 5). It is not meant to be prescriptive:

1. Detection of intrathoracic complications

Acute clinical deterioration that is not elucidated by a portable radiograph may require chest CT. Such examples include exclusion of an empyema or lung abscess. These necessitate different management approaches and are difficult to differentiate on chest radiography. If possible, contrast-enhanced CT is indicated in this clinical setting.

CT pulmonary angiography should be performed in the setting of suspected acute pulmonary embolism (PE). The actual incidence of venous thromboembolism (VTE) in this population is not well established. Unpublished data from colleagues around the world suggest a high incidence of VTE, despite the use of thrombo-prophylaxis, e.g. 26/110 CT performed upon admission in the ICU were positive for PE (Strasbourg, France), 15% in Cremona, Italy. In Cornell, NYC, an overall incidence of 3% was observed in COVID-19 patients regardless of severity, with an 8.4% incidence among intubated patients.

2. Immunosuppressed or high-risk patients with suspected respiratory infection and a negative chest radiograph

Immunosuppressed patients are at higher risk of opportunistic infections including viral infections. Recent data from Italy suggests that unlike other viruses such as influenza, respiratory syncytial virus and adenovirus, the family of coronaviruses that includes SARS-CoV-2 responsible COVID-19 disease is not associated with more severe disease in immunosuppressed patients. Rather, it is the host's innate immune response that is the driver of acute lung injury related to infection[11]. However, COVID-19 positive patients with solid malignant tumours who were immunosuppressed due to chemotherapy and those with recent immune therapy or radiation treatment had worse outcomes in Wuhan, China[12]. Therefore, due to the higher risk of lung infection in immunosuppressed patients in general, it is reasonable to image these patients with CT chest.

Another group of high-risk individuals has been identified in a large cohort of patients from Wuhan, China. These patients have a higher incidence of disease progression and worse outcomes. High-risk factors which include age >65 years, cardiovascular disease, diabetes, chronic respiratory disease and hypertension[4].

COVID-19 lung infection is often associated with subtle ground-glass opacities that may be difficult to visualize or occult on chest radiographs[6]. Therefore, in the immune-suppressed populations, chest CT may be considered to evaluate for COVID-19 just as it is routinely used in some institutions to evaluate for pulmonary infection in leukemic patients with febrile neutropenia. This may be especially important if there are delays in obtaining RT-PCR results or

local constraints on RT-PCR testing. However, a normal chest CT does not exclude COVID-19 infection.

3. Initial negative RT-PCR result but ongoing high clinical suspicion or clinical deterioration after a normal chest radiograph

In the early stages of infection, viral load may be too small to be detected by RT-PCR and reports in the literature suggest that CT chest findings may be present even in asymptomatic COVID-19 infected patients[13]. Furthermore, the CT chest may be useful to identify an alternative cause for a patient's symptoms. When there is clinical deterioration, CT chest can be performed for re-evaluation of the patient who may have had a previous negative RT-PCR swab result or non-contributory chest radiographs to evaluate for underlying causes. This indication is also endorsed by the recently published Fleischner Society statement[6].

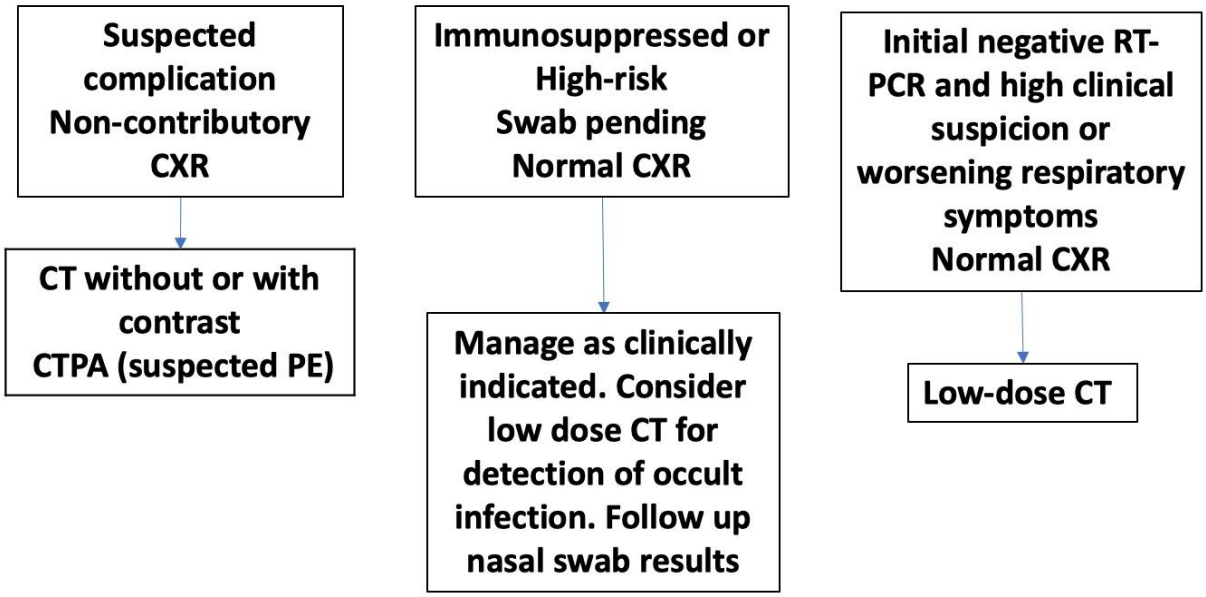

Figure 5 – Potential clinical scenarios in which CT chest may be helpful

In certain healthcare settings, due to local circumstances, the use of chest CT has been expanded to include:

Patients undergoing CT for other reasons or planned for urgent surgery or intervention

In this developing expanded indication, a CT of the head or abdomen is already requested and the CT chest is added.
Such clinical scenarios include:

- Stroke code patients
- Patients in need of urgent interventional radiology procedures

- Patients with acute abdominal pain potentially in need of urgent abdominal surgery (ruptured appendicitis etc.).
- Patients with abdominal pain of unknown cause undergoing CT abdomen

The use of CT chest in the first three scenarios may be motivated by the needs of anaesthesia and surgical departments to triage the use of PPE to adequately protect health care workers, to risk stratify patients and appropriately allocate health care resources. In many hospitals, RT-PCR results may take up to 24 hours and there may be reductions in "real-world" sensitivity due to problems with sampling technique (nasopharyngeal swab may have greater sensitivity versus throat swab)[14].

When there is a need for an urgent intervention or procedure, waiting 24 hours for the swab result to decide on the level of PPE required is impractical. CT chest is used as supplementary information to guide the use of PPE. Full PPE precautions are used when the RT-PCR is pending or unknown and the CT chest demonstrates typical or non-specific findings of COVID-19. A positive CT chest can also help risk stratify patients because asymptomatic lung infection may influence the decision to proceed with surgery or delay if clinically feasible.

In cases where the RT-PCR result is unknown or pending and the patient needs urgent intervention or surgery, a negative chest CT is felt to indicate a lower risk of COVID-19 especially in a low pre-test likelihood patient who is asymptomatic from a respiratory standpoint. A lower level of PPE could potentially be used in these patients. It is important to note that early in disease course, chest CTs can be entirely normal in patients with a positive RT-PCR. Bernheim et al. demonstrated this in 20/36 (54%) patients within 2 days of symptom onset[13]. Therefore, a normal CT chest may be falsely reassuring and may not be helpful to inform on the type of PPE used.

CT chest is also unlikely to be useful if full PPE precautions are employed in all patients undergoing urgent surgery or intervention (all patients treated as if they were COVID-19 positive). This strategy is also impractical if there are local constraints with respect to CT scanner and PPE availability.

The rationale to add a CT chest to a CT abdomen in patients with undifferentiated abdominal pain stems from the fact that COVID-19 pneumonia may present with upper abdominal symptoms secondary to disease in the lung bases. The clinical differentiation between lower chest and upper abdominal pain may be challenging. Less commonly, COVID-19 infection presents with abdominal symptoms rather than fever, dry cough and shortness of breath. In a recent meta-analysis, a pooled prevalence demonstrated that 17.6% of COVID-19 infected patients had gastrointestinal symptoms and 48.1% had viral RNA detected in stool samples[15].

In summary, there is currently no published data demonstrating outcome benefit to adding chest CT to CT head or abdomen and several current society guidelines do not specifically mention or endorse this strategy. The recently published Fleischner Society statement

specifically states that no imaging is required for mild cases of COVID-19 infection but does not address scenarios involving asymptomatic patients[6].

Our understanding of the utility of chest CT in the evaluation of COVID-19 continues to evolve and will be informed by ongoing data collection and research.

Recommendations on reporting chest CT findings

Adoption of standardized language is recommended by the CSTR and has also been advocated by other radiological societies including the RSNA[16] and the Fleischner Society [6]. It is felt that this will lessen variability in the interpretation of CT findings and facilitate correct identification of frequently and infrequently reported imaging features in this clinical context. It is hoped that in this manner, consultation and relay of diagnostic information is enhanced between the radiologists and their referring colleagues, resulting in better clinical decision making. Our recommendations are based on the available scientific evidence to date and are subject to revision in the near future as more scientific data on COVID-19 is gathered and analyzed[17]. Implementation of structured reporting is preferably carried out in consultation with clinical colleagues at each facility as this practice may potentially introduce certain limitations in patient management if the terminology "COVID-19" is incorporated into a patient's report.

It is suggested that the provided template and language be utilized at the discretion of the interpreting radiologist and in the setting of suspected pneumonia, which could include COVID-19 as a diagnostic possibility. The template does not apply to lung findings on CT done for other indications. It is strongly recommended that radiologists review and familiarize themselves with CT findings which have been frequently[13, 18-20] and infrequently[13, 20] reported with COVID-19 pneumonia. The CSTR recommends consolidation of all imaging features which are not typical or seen rather infrequently with COVID-19 into a single category termed *non-specific.* This is intended to simplify the diagnostic and reporting process and stems from unpublished reports of patients with CT findings currently considered atypical of COVID-19 pneumonia who subsequently tested positive for the infection. The potential clinical and societal ramifications of reporting such findings as atypical and hence implying a significantly reduced likelihood of the infection is not felt to be insignificant. It is crucial to note that a CT examination depicting typical findings of COVID-19 pneumonia is not diagnostic of the condition[21-23]. A CT examination demonstrating non-specific findings is neither supportive nor refuting a diagnosis of COVID-19 infection with any degree of confidence[21-23]. In addition, a negative CT examination does not exclude the possibility of the infection as a significant number of patients have been reported to have a normal CT in the early stages of the disease[13, 21, 24, 25].

Suggested categorization and reporting language

If the examination shows typical findings, the term "*typical appearance*" is suggested. The recommended language for the final impression of the report is: *"In the appropriate clinical setting, these imaging features are considered typical of COVID-19 pneumonia but can also be*

seen in other types of viral pneumonia such as influenza pneumonia and with drug reaction and organizing pneumonia" (Figures 6, 7 & 8).

If the examination shows non-specific findings, the term "*non-specific appearance*" is suggested. The recommended language for the final impression of the report is: *"The imaging features are non-specific and may be attributable to a variety of causes such as infection, including but not exclusive to COVID-19 pneumonia and inflammatory conditions. It is recommended that further management be based on non-imaging parameters of the presentation"* (Figure 9).

If the examination shows no findings which could be attributable to any type of pneumonia, the term "*negative for pneumonia*" is recommended. The recommended language for the final impression of the report is: "*The examination is negative for pneumonia. Note that a negative CT does not exclude COVID-19 infection especially early in the disease."* The imaging findings and proposed reporting structure are summarized in Table 2.

Table 2 – CT findings and proposed reporting structure in patients with suspected or confirmed COVID-19

Categories	Rationale	CT Findings	Proposed Reporting Language
Typical appearance (Figures 6, 7 & 8)	Presently have a higher specificity for COVID-19 pneumonia	-Rounded, multifocal GGO with or without consolidation or crazy-paving -Peripheral & bilateral GGO with or without consolidation or crazy-paving -Lower zone predominance -Findings characteristic of organizing pneumonia such reverse halo sign (seen in the latter stages of the disease)	In the appropriate clinical setting, these imaging features are considered typical of COVID-19 pneumonia but can also be seen in other types of viral pneumonia such as influenza pneumonia and with a drug reaction or organizing pneumonia.

Non-specific appearance (Figure 9)	Non-specific findings, not as commonly reported for COVID-19 pneumonia	-Non-rounded and non-peripheral GGO of any size with/without consolidation void of a specific distribution (unilateral or bilateral, central zonal) -Isolated consolidation either lobar or segmental without GGO -Small and discrete centrilobular nodules with or without "tree-in-bud" -Lung cavitation -Smooth interlobular septal thickening with pleural effusion -Lymphadenopathy	The imaging features are non-specific and may be attributable to a variety of causes such as infection, including but not exclusive to COVID-19 and inflammatory conditions. It is recommended that further management be based on non-imaging parameters of the presentation.
Negative for pneumonia	Findings are either absent or non-contributory towards a pneumonia diagnosis	Lack of any findings to suggest pneumonia	"Negative for pneumonia. Note that a negative CT does not exclude COVID-19 infection especially early in the disease."

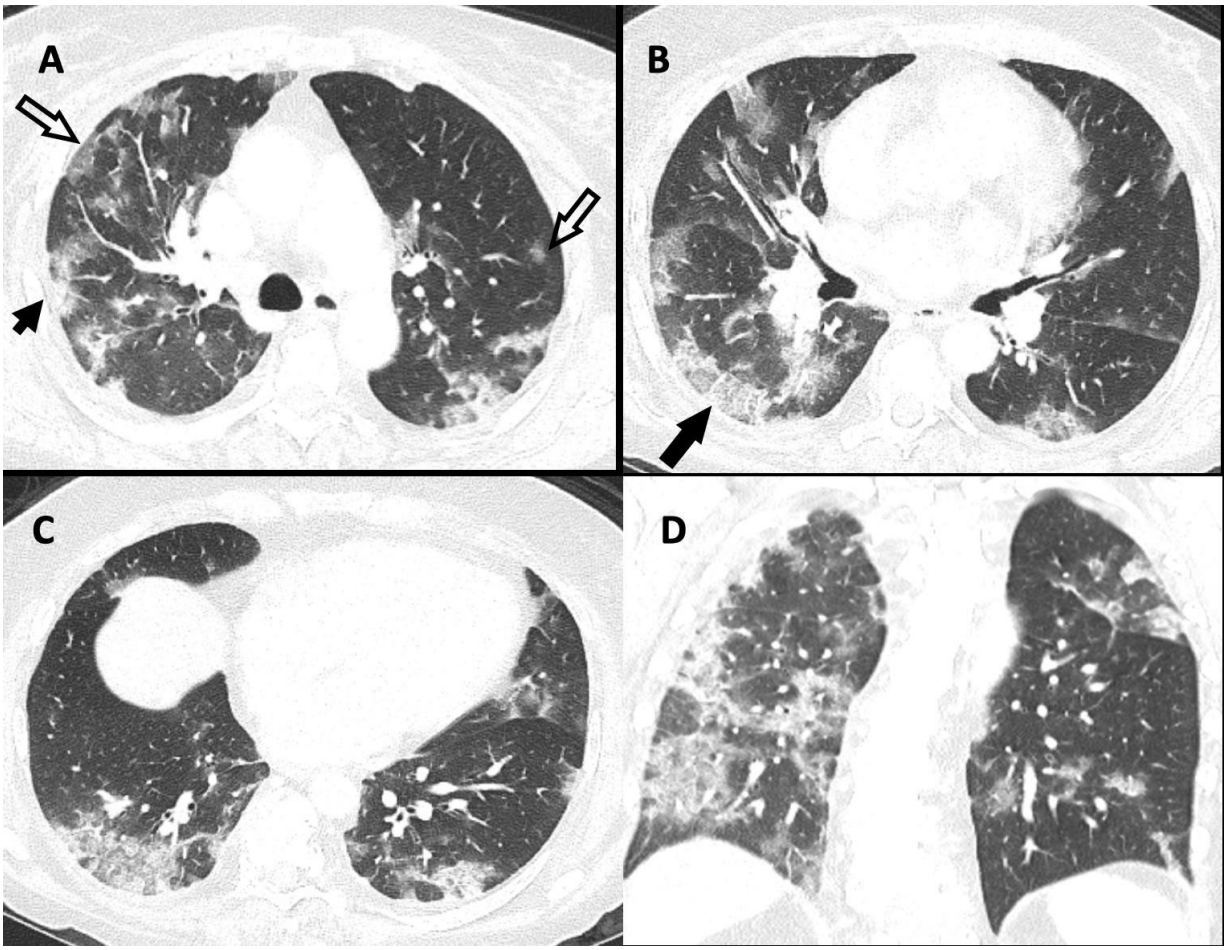

Figure 6 – CT chest depicting "*typical appearance*". Select thin-section axial (A-C) and coronal (D) images of the lungs from an unenhanced CT in a 61-year-old woman with a positive RT-PCR presenting to ED with a 10-day history of progressive shortness of breath, fever, cough, malaise and watery diarrhea. There are multifocal, peripheral and occasionally rounded GGO (open arrows) with consolidation (short arrow) and crazy-paving (long arrow).

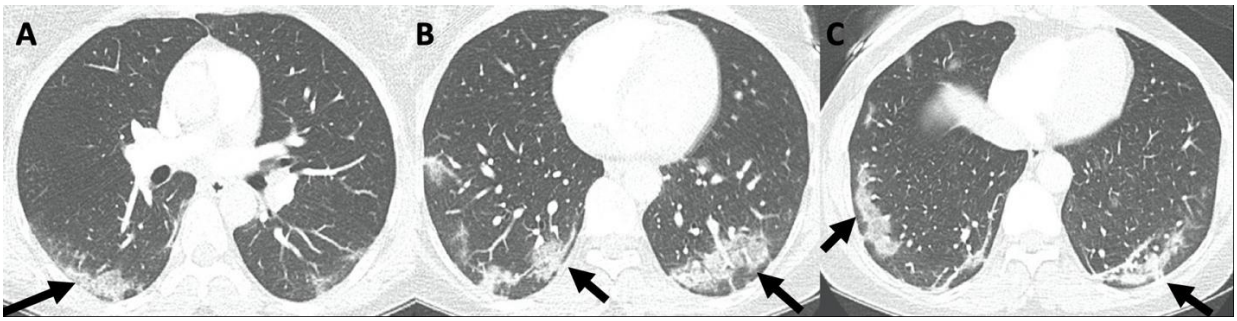

Figure 7 – CT chest depicting *"typical appearance*". Axial images of the lungs (A-C) from a CT pulmonary angiogram in a 48-year-old woman with a history of remote DVT who presented to the ED with chest pain and hemoptysis and subsequently had a positive RT-PCR test for COVID-19 demonstrate peripheral and multifocal GGO and consolidation with an organizing pneumonia pattern (arrows).

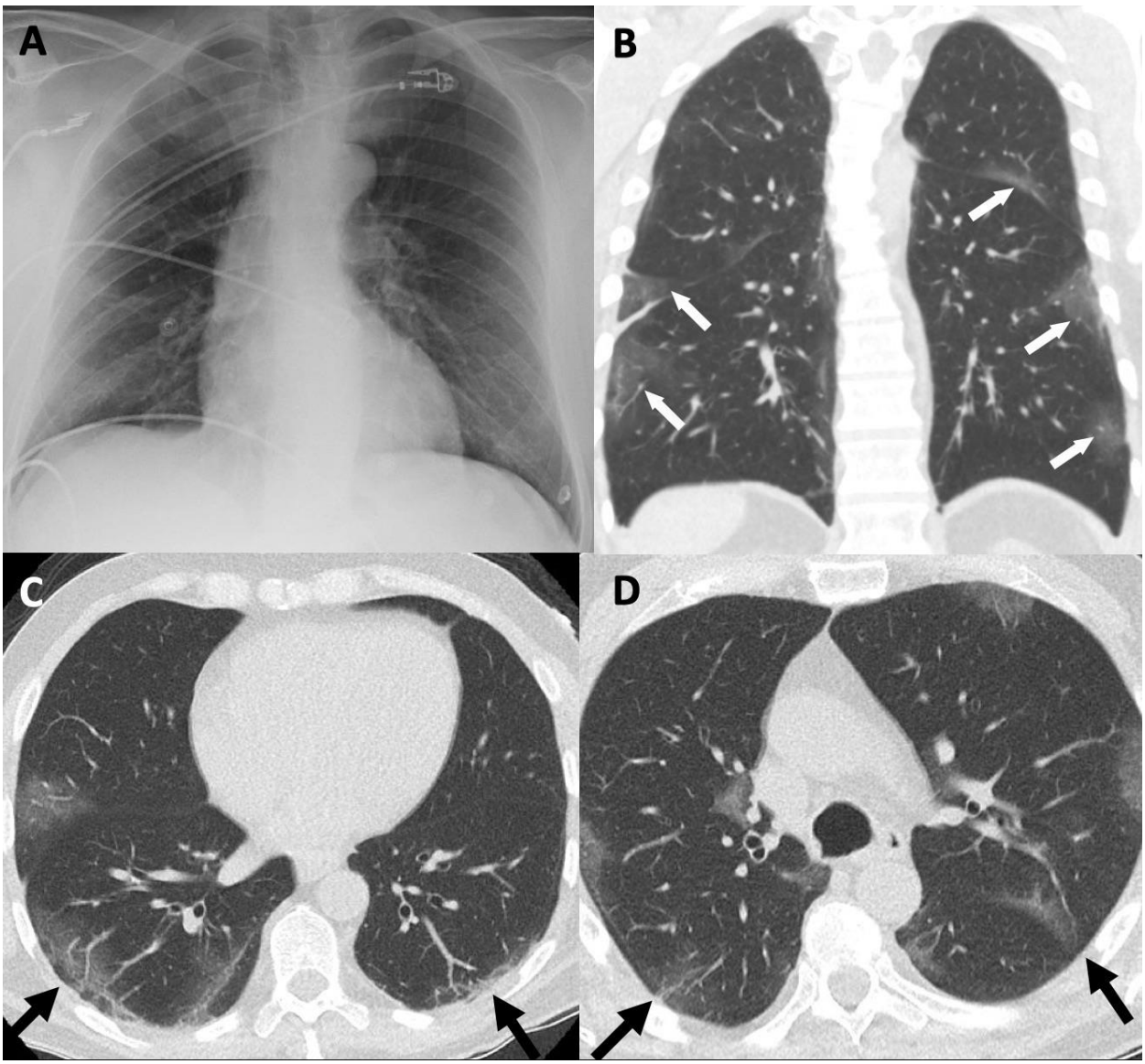

Figure 8 - "*Typical appearance*". 58-year-old man with positive RT-PCR assay for COVID-19 with a 9-day history of worsening symptoms including shortness of breath. Normal or near normal portable chest radiograph (A) and coronal (B) and axial CT low-dose CT obtained 1-hour later demonstrate peripheral GGO with slight lower zone predominance (arrows).

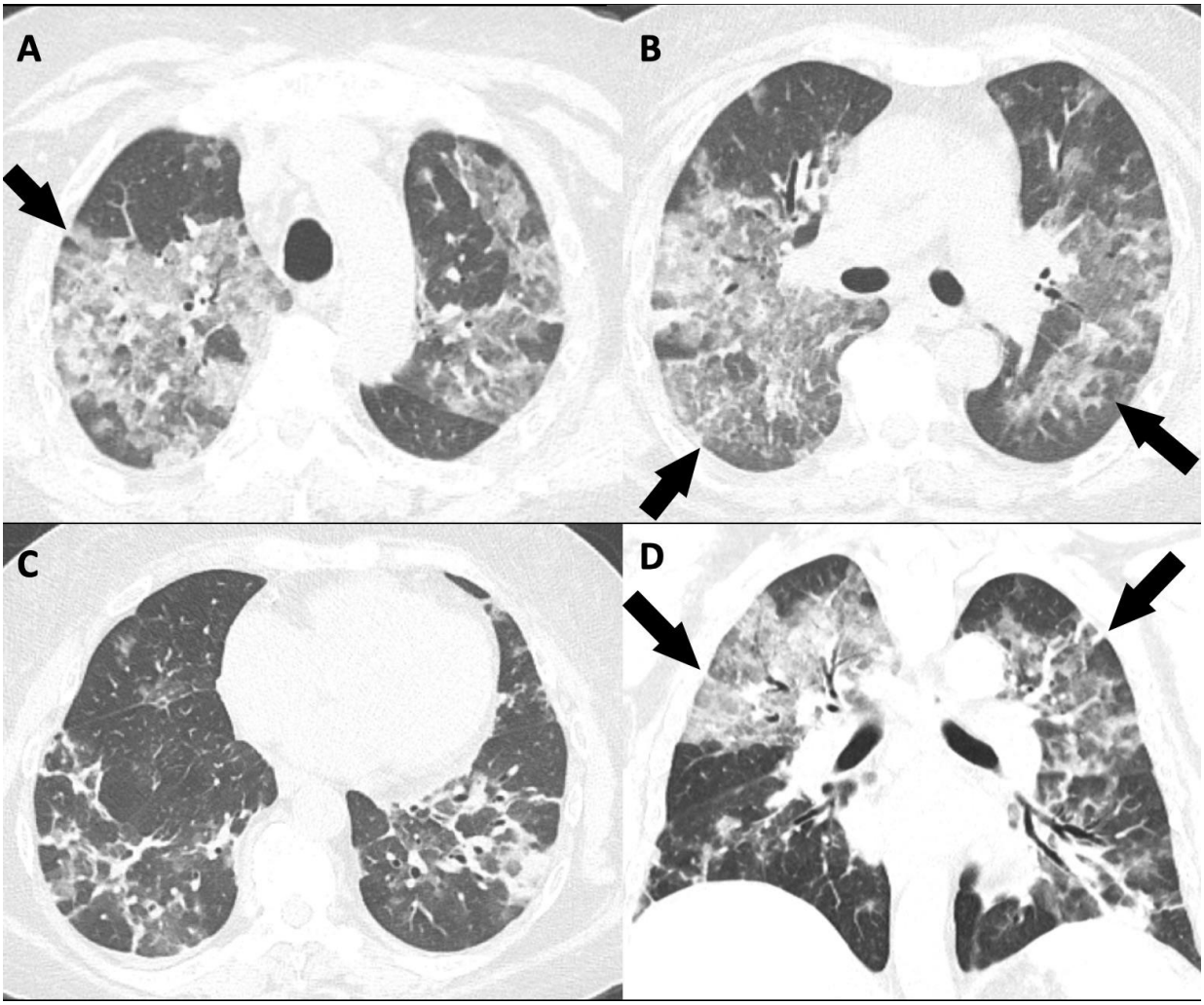

Figure 9 – CT chest depicting "*non-specific appearance*". Unenhanced axial (A-C) and coronal (C) CT images (lung reconstruction) in a 55-year-old woman with chronic renal insufficiency presenting to hospital with a one-week history of cough, shortness of breath, malaise and low-grade fever. RT-PCR was positive for COVID-19. CT reveals non-rounded, non-peripheral GGO with upper zone predominance (arrows).

How should a radiologist deal with incidental findings of COVID-19 on CT chest done for other indications?

When typical or non-specific features of COVID-19 pneumonia are seen as an incidental finding in endemic areas, the CSTR recommends that the interpreting radiologist should contact the most responsible provider directly to discuss the likelihood of viral infection. Caution must be exercised in the wording of the radiology report as documentation of "COVID-19" may constrain clinical decision making and treatment options. RSNA recommendations emphasize

the use of direct communication with the referring physician and wording such as "viral pneumonia" may be preferable in the setting of incidentally detected lung abnormalities[16].

The reporting template and suggested language for CT done in patients with suspected pneumonia described previously does not apply to lung findings on CT done for other indications.

There are currently few reports on the detection of CT findings suggestive of a diagnosis of COVID-19 pneumonia as an incidental finding on CT chest done for other clinical indications. Albano and his colleagues reported on 65 patients in Italy who underwent PET/CT for routine oncology indications during the third week of March 2020. Patients were screened by questionnaire for symptoms and exposure and there was no indication to suspect COVID-19 infection. Of these 65 patients, 6 showed signs of pneumonia on CT as an incidental finding and 5/6 subsequently tested positive for COVID-19[26]. Although not a study of incidental findings on chest CT, imaging findings in 112 cases of COVID-19 positive patients on board the "Diamond Princess" cruise ship were analyzed[27]. 54% of asymptomatic patients who tested positive for COVID-19 had abnormal findings on chest CT. No significant differences in age, gender, or comorbidities were identified in symptomatic vs asymptomatic cases. Asymptomatic patients showed a lower CT severity score and predominant GGO whereas symptomatic patients showed predominant consolidation.

Given that there is now community spread in most areas in the country and asymptomatic patients can have positive CT findings in over 50% of cases, there is likely a significant chance of encountering findings suggestive of COVID-19 on CT chest performed for other indications in asymptomatic patients who do not have known COVID-19 exposure (Figure 9 & 10).

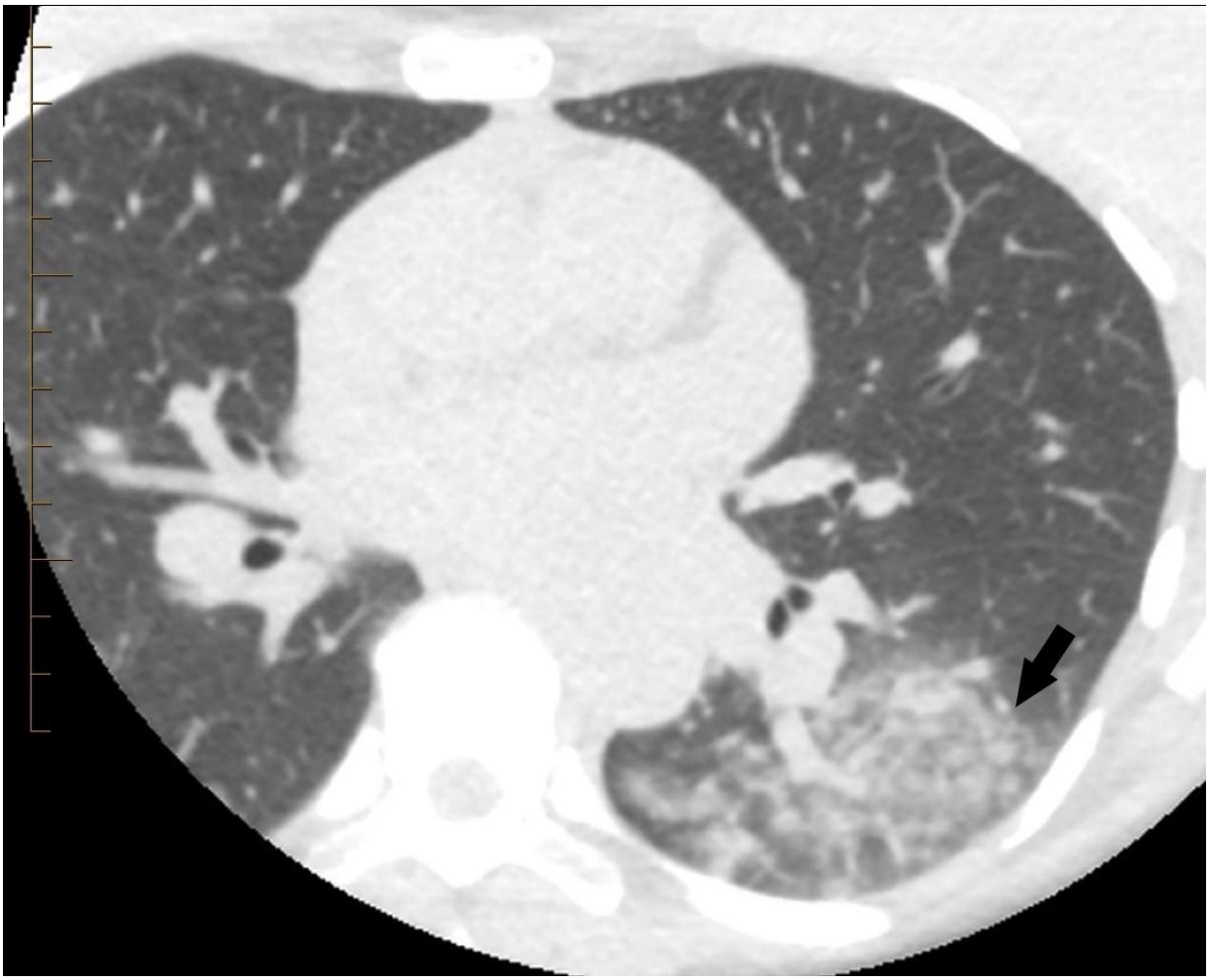

Figure 10 – Incidental detection of COVID-19 pneumonia on CT chest done for another clinical indication. Axial image (lung reconstruction) from a cardiac CT in 50-year-old female nurse with asthma, a family history of coronary artery disease and an 18-month history of ongoing chest discomfort depicts non-specific mixed ground-glass and airspace opacities (arrow) in the left lower lobe. The patient's physician was alerted of the unexpected findings. Although asymptomatic from a respiratory standpoint, subsequent RT-PCR swab was positive for COVID-19. Two days later, the patient developed a dry cough but no other symptoms.

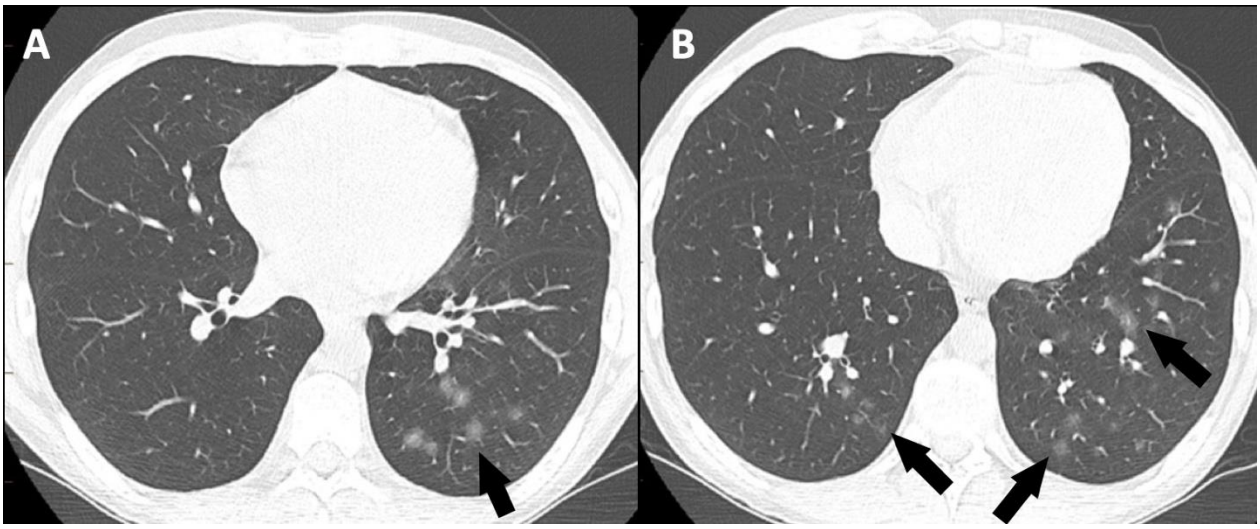

Figure 11 – Incidental detection of GGO on CT chest done for another clinical indication. Is this COVID-19 pneumonia? Select thin-slice axial images of the lungs (A & B) from an unenhanced CT performed to rule out post-transplant lymphoproliferative disorder in a 22-year-old asymptomatic man 3-years post-renal transplantation. CT shows subtle lower zone rounded GGO (arrows). The patient remained asymptomatic and had consecutive swabs for RT-PCR testing which were all negative for COVID-19.

Should lung ultrasound (LUS) be used to diagnose or exclude COVID-19 pneumonia?

LUS should not be used to diagnose or exclude COVID-19 pneumonia. While there is a growing identification of lung ultrasound patterns in COVID-19 pneumonia[28-31], the overlap with other causes of respiratory distress is unknown. Small outcome studies have been performed in patients with other causes of acute respiratory distress[32-34] but are insufficient to support the use of LUS to contribute to or supersede established prognostic tools, such as the Sequential Organ Failure Assessment (SOFA) score[35]. Any use of LUS in COVID-19 patients should be done within the context of a controlled research study, ideally with operators blinded to other clinical markers of severity. Risks of viral exposure to operators is unknown but some authors suggest the exam should only be performed by those already caring for the patient in another capacity[28].

Conclusion

The CSTR/CAR consensus statement above is based on knowledge acquired thus far as we navigate this uncertain time. As the evidence for imaging in COVID-19 evolves, our opinions and recommendations will be refined over time.

References

1. Wong HYF, Lam HYS, Fong AH, et al. Frequency and Distribution of Chest Radiographic Findings in COVID-19 Positive Patients. *Radiology*. 2019: 201160.
2. Hosseiny M, Kooraki S, Gholamrezanezhad A, Reddy S and Myers L. Radiology Perspective of Coronavirus Disease 2019 (COVID-19): Lessons From Severe Acute Respiratory Syndrome and Middle East Respiratory Syndrome. *AJR Am J Roentgenol*. 2020: 1-5.
3. People who are at higher risk for severe illness | Coronavirus | COVID-19 | CDC.
4. Wu Z. MJM. Characteristics of an important lessons from the coronavirus disease 2019 (COVID-19) outbreak in China: summary of a report of 72314 cases from the Chinese Center for Disease Control and Prevention. *Journal of the American College of Medicine*. 2020; 323: 1239-42.
5. Shi H, Han X, Jiang N, et al. Radiological findings from 81 patients with COVID-19 pneumonia in Wuhan, China: a descriptive study. *Lancet Infect Dis*. 2020; 20: 425-34.
6. Rubin GD, Ryerson CJ, Haramati LB, et al. The Role of Chest Imaging in Patient Management during the COVID-19 Pandemic: A Multinational Consensus Statement from the Fleischner Society. *Chest*. 2020.
7. Oba Y and Zaza T. Abandoning daily routine chest radiography in the intensive care unit: meta-analysis. *Radiology*. 2010; 255: 386-95.
8. Cao AM, Choy JP, Mohanakrishnan LN, Bain RF and van Driel ML. Chest radiographs for acute lower respiratory tract infections. *Cochrane Database Syst Rev*. 2013: CD009119.
9. Zwirewich CV, Mayo JR and Muller NL. Low-dose high-resolution CT of lung parenchyma. *Radiology*. 1991; 180: 413-7.
10. Christe A, Charimo-Torrente J, Roychoudhury K, Vock P and Roos JE. Accuracy of low-dose computed tomography (CT) for detecting and characterizing the most common CT-patterns of pulmonary disease. *Eur J Radiol*. 2013; 82: e142-50.
11. D'Antiga L. Coronaviruses and immunosuppressed patients. The facts during the third epidemic. *Liver Transpl*. 2020.
12. Zhang L, Zhu F, Xie L, et al. Clinical characteristics of COVID-19-infected cancer patients: A retrospective case study in three hospitals within Wuhan, China. *Ann Oncol*. 2020.
13. Bernheim A, Mei X, Huang M, et al. Chest CT Findings in Coronavirus Disease-19 (COVID-19): Relationship to Duration of Infection. *Radiology*. 2020: 200463.
14. Yang Y. MY, Shen C., Wang F., Yuan J, Li, J., Zhang M., Wang Z., Xing L, Wei J., Peng L., Wong G., Zheng H., Liao M., Feng K., Li J., Yang Q., Zhao J., Zhang A., Liu L., Liu Y. Evaluating the accuracy of idfferent respiratory specimens in the laboratory diagnosis and monitoring the viral shedding of 2019-nCoV infections. *medRxiv*. 2020.
15. Cheung KS, Hung IF, Chan PP, et al. Gastrointestinal Manifestations of SARS-CoV-2 Infection and Virus Load in Fecal Samples from the Hong Kong Cohort and Systematic Review and Meta-analysis. *Gastroenterology*. 2020.
16. Simpson S. KFU, Abbara S., Bhalla S., Chung J.H., Chung M., Henry T.S., Kanne J.P., Kligerman S., Ko J.P., Litt H. Radiological Society of North America expert consensus statement on reporting chest CT findings related to COVID-19. Endorsed by the Society

of Thoracic Radiology, the American College of Radiology, and RSNA. *Radiology: Cardiothoracic Imaging*. 2020; 2.
17. Ye Z. ZY, Wang Y., Huang Z., Song B. Chest CT manifestations of new coronavirus disease 2019 (COVID-19): a pictorial review. *European Radiology*. 2020.
18. Kong W. A, P.P. Chest imaging appearance of COVID-19 infection. *Radiology: Cardiothoracic Imaging*. 2020; 2.
19. Salehi S, Abedi A, Balakrishnan S and Gholamrezanezhad A. Coronavirus Disease 2019 (COVID-19): A Systematic Review of Imaging Findings in 919 Patients. *AJR Am J Roentgenol*. 2020: 1-7.
20. Ng M. LEYP, Yang J., Yang F., Li X., Wang H., Lui M. M., Lo C. S., Leung B., Khong P., Hui C.K., Yuen K., Kuow M.D. Imaging profile of the COVID-19 infection: Radiologic findings and literature review. *Radiology: Cardiothoracic Imaging*. 2020; 2.
21. Ai T, Yang Z, Hou H, et al. Correlation of Chest CT and RT-PCR Testing in Coronavirus Disease 2019 (COVID-19) in China: A Report of 1014 Cases. *Radiology*. 2020: 200642.
22. Wen Z. CY, Zhang L., Liu H., Du K., Zhengxing L., Chen J., Cheng L., Wang D. Coronavirus disease 2019: Intitial detection on chest CT in a retrospective multicenter study of 103 Chinese subjects. *Radiology: Cardiothoracic Imaging*. 2020; 2.
23. Fang Y, Zhang H, Xie J, et al. Sensitivity of Chest CT for COVID-19: Comparison to RT-PCR. *Radiology*. 2020: 200432.
24. Pan F, Ye T, Sun P, et al. Time Course of Lung Changes On Chest CT During Recovery From 2019 Novel Coronavirus (COVID-19) Pneumonia. *Radiology*. 2020: 200370.
25. Huang L. HR, Ai T., Yu P., Kang H., Tao Q., Xia L. Serial quantitative chest CT assessment of COVID-19: Deep-learning approach. *Radiology: Cardiothoracic Imaging*. 2020; 2.
26. Albano D, Bertagna F, Bertolia M, et al. Incidental Findings Suggestive of Covid-19 in Asymptomatic Patients Undergoing Nuclear Medicine Procedures in a High Prevalence Region. *J Nucl Med*. 2020.
27. 27. Inui S. FA, Jitsu M., Kunishima N., Watanabe S., Suzuki Y., Umeda S., Uwabe Y. Chest CT findings in cases from the cruise chip "Diamond Princess" with coronavirus disease 2019 (COVID-19). *Radiology: Cardiothoracic Imaging*. 2020; 2.
28. Buonsenso D, Piano A, Raffaelli F, Bonadia N, de Gaetano Donati K and Franceschi F. Point-of-Care Lung Ultrasound findings in novel coronavirus disease-19 pnemoniae: a case report and potential applications during COVID-19 outbreak. *Eur Rev Med Pharmacol Sci*. 2020; 24: 2776-80.
29. Poggiali E, Dacrema A, Bastoni D, et al. Can Lung US Help Critical Care Clinicians in the Early Diagnosis of Novel Coronavirus (COVID-19) Pneumonia? *Radiology*. 2020: 200847.
30. Peng QY, Wang XT, Zhang LN and Chinese Critical Care Ultrasound Study G. Findings of lung ultrasonography of novel corona virus pneumonia during the 2019-2020 epidemic. *Intensive Care Med*. 2020.
31. Roth K.R. Z, J.B., Crowley L.M., Greenberg M.R. Computed tomography and Point-of-care ultrasound findings in two COVID-19 patients. *Annals of Emergency Medicine*. 2020.
32. Laursen CB, Sloth E, Lassen AT, et al. Point-of-care ultrasonography in patients admitted with respiratory symptoms: a single-blind, randomised controlled trial. *Lancet Respir Med*. 2014; 2: 638-46.

33. Mongodi S, Pozzi M, Orlando A, et al. Lung ultrasound for daily monitoring of ARDS patients on extracorporeal membrane oxygenation: preliminary experience. *Intensive Care Med*. 2018; 44: 123-4.
34. Soummer A, Perbet S, Brisson H, et al. Ultrasound assessment of lung aeration loss during a successful weaning trial predicts postextubation distress*. *Crit Care Med*. 2012; 40: 2064-72.
35. Vincent JL, de Mendonca A, Cantraine F, et al. Use of the SOFA score to assess the incidence of organ dysfunction/failure in intensive care units: results of a multicenter, prospective study. Working group on "sepsis-related problems" of the European Society of Intensive Care Medicine. *Crit Care Med*. 1998; 26: 1793-800.